

SUBSCAPULARIS TENDON

LATEST IDEAS AND OUR TREATMENT PRINCIPLES

– Written by Yong Bok Park and Jae Chul Yoo, Korea

SUBSCAPULARIS & ATHLETES

The subscapularis muscle is the largest and strongest muscle of the rotator cuff. It plays an essential role in the stability and function of the shoulder. Historically, subscapularis tendon tears were thought to be relatively uncommon, particularly in comparison to supraspinatus and infraspinatus tendon tears. However, as shoulder arthroscopy techniques have improved, recognition of subscapularis tendon tears has increased, with a prevalence of nearly 50% in all arthroscopic shoulder surgeries^{1,2}.

In the setting of sports injury, subscapularis tendon injury is associated with isolated subscapularis tendon tear and frequently occurs with trauma of the shoulder in abducted, externally rotated and hyperextended positions³. As well as acute trauma, overuse or improper technique during overhead phases of throwing,

swinging or swimming could put athletes at risk of subscapularis tendon injury.

Because it is difficult for athletes to regain preoperative levels of activity after surgery⁴, surgical indication for elite athletes is very important. Thus, the severity of the injury based on anatomy is critical in determining whether or not to operate. There are several anatomy studies in the literature⁵⁻¹⁰; all describe the subscapularis tendon insertion footprint as a two-dimensional area in the coronal plane. Some studies describe it as a 'comma shape'^{6,8} or 'State of Nevada'⁹. More recent studies better describe the footprint anatomy; however it is somewhat confusing when we are dealing with three-dimensional arthroscopic milieu. A better understanding of the subscapularis footprint anatomy in a 3D perspective would help more accurately define tear size, especially arthroscopically, and potentially understand the tear pattern. Furthermore,

this tear pattern recognition will enable us to develop a better classification system than is currently reported in the literature⁵⁻¹². With better description of the tear classification we will be better equipped to manage subscapularis tendon injuries both in athletic and non-athletic populations.

THE 3D PERSPECTIVE OF SUBSCAPULARIS TENDON INSERTION

The insertion of the subscapularis is located on the lesser tuberosity and a portion of the proximal humerus. The subscapularis muscle arises from the anterior surface of the scapula. Four to six thick collagen bundles that originate from the muscle belly insert at the lesser tuberosity. A number of fibres extend laterally and superiorly to form the medial wall of the biceps tendon groove and merge with the supraspinatus tendon. At the inferior part, the subscapularis tendon becomes shorter and at the lowest part, the

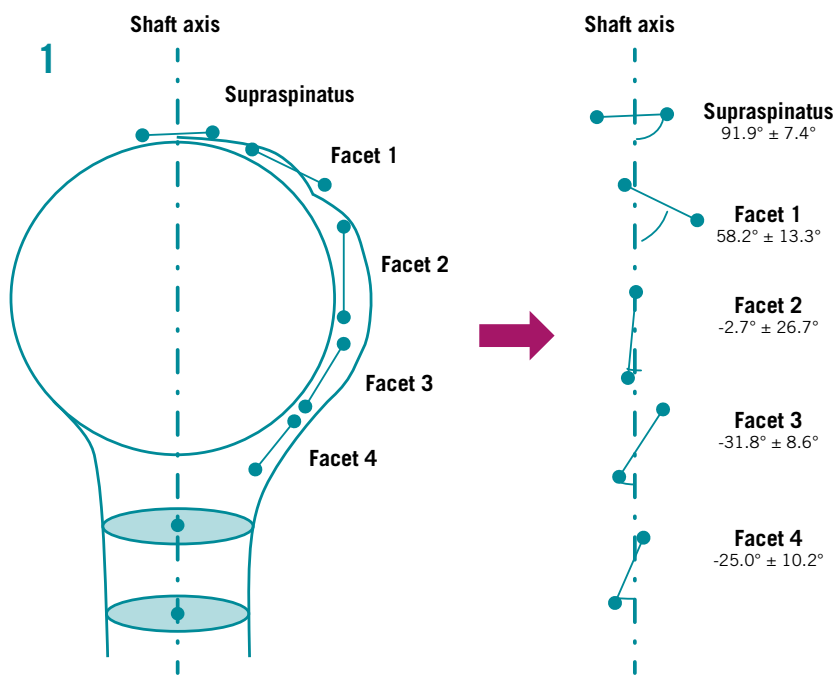
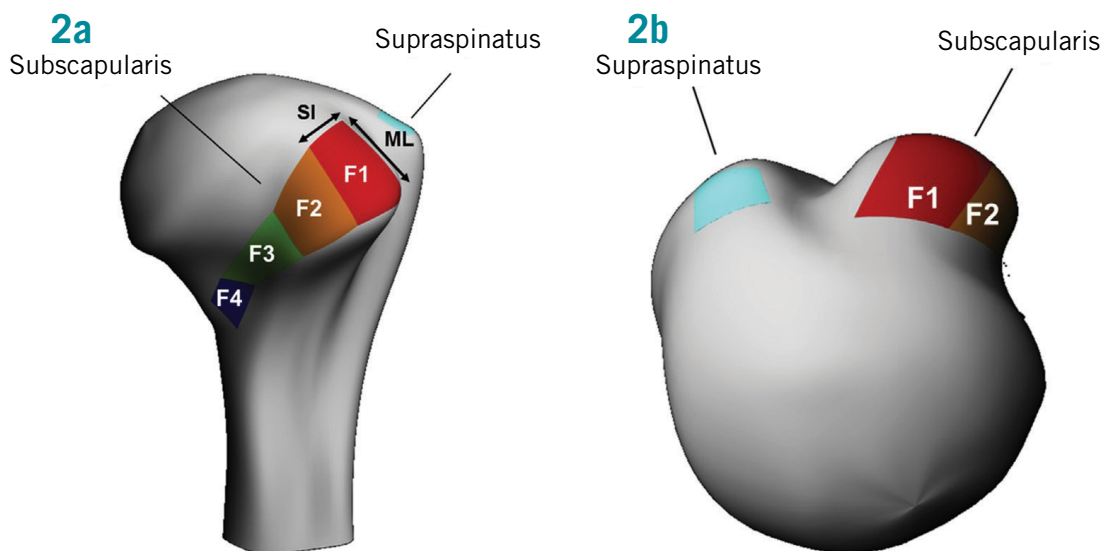


Figure 1: Facet angle calculation relative to the humeral shaft axis showing the mean and standard deviation for each facet. First 2 facets seem to have balancing angle with supraspinatus/infraspinatus footprint insertion.

Figure 2: Reconstruction of the proximal humerus and its subscapularis footprint outlined in different colors. The supraspinatus first facet is outlined to compare with each of the facets of the subscapularis footprint from superior facet 1 (F1) to most inferior facet 4 (F4). The superior-inferior (SI) dimension and medial-lateral (ML) dimension are outlined: (a) coronal plane and (b) transverse plane.



insertion is almost purely muscular. The insertion of the subscapularis tendon is mostly located on the lesser tuberosity of the proximal humerus. Most subscapularis tendon tears are commonly located in the cranial part or upper two-thirds of the tendon (sometimes called a 'leading edge' tear).

A recent study conducted by the authors using Microscribe (Revware, Raleigh, NC)¹³, found the footprint of the subscapularis tendon on the lesser tuberosity seems to have four different planes of insertion, which we termed 'facets'. The first facet is roughly a 13.8 x 13.5 mm rectangle (the best fit model). The superior two facets represent about 60% of the entire subscapularis insertion area, which might suggest that complete subscapularis tendon rupture,

which was commonly documented in the literature, refers to this area (the tendinous portion of subscapularis tears). The incidence of subscapularis tendon tears with complete rupture of these two facets or insertion areas was reported to be low. However, recently some studies reported the incidence to be as high as 50%, including our prospective 2-year observations^{5,11,13,14}. Also, in patients older than 50 years undergoing shoulder arthroscopy, approximately 50% or more will have some form of subscapularis partial or complete tears with or without other shoulder pathologies¹³.

Regarding the plane insertion angle, the first facet is closer to the angle of the supraspinatus tendon's first facet insertion; whereas, the angle of the second facet of the

subscapularis is almost parallel with the humeral shaft (Figure 1).

This suggests that the first facet of the subscapularis tendon might play a greater role in abduction (elevation) than rotation, especially compared with the remaining subscapularis insertions. Previous studies stated that the subscapularis tendon plays an important role as an elevator and stabiliser of the glenohumeral joint^{15,16}. In their positron emission tomography study, Omi et al¹⁷ also showed that the superior third plays an important role during arm elevation in the scapular plane (Figure 2).

Identifying the footprint of the first facet and its involvement in the 'lateral hood' can be important in classifying upper third partial and complete one-third tears. Lateral

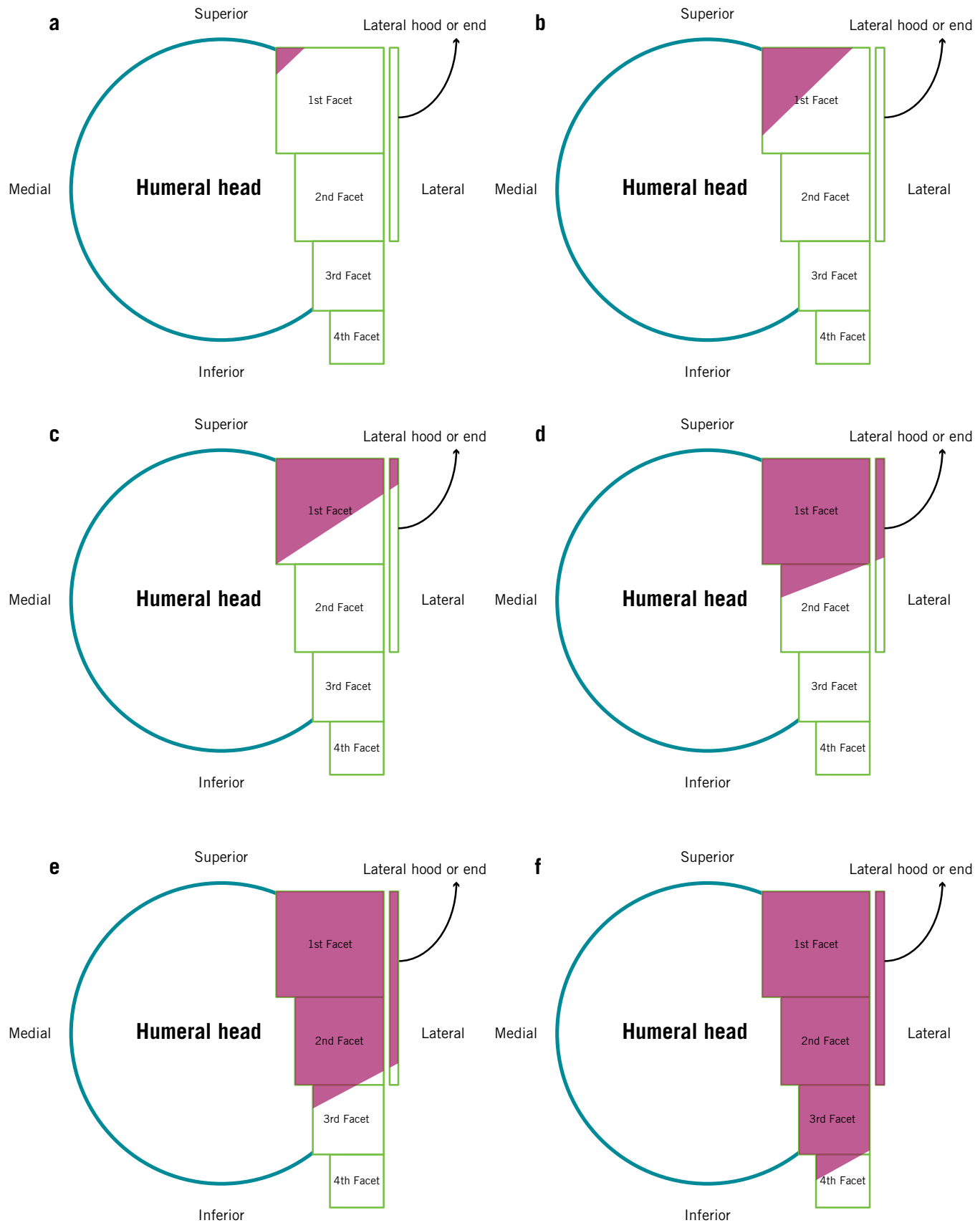


Figure 3: This figure shows tear patterns. Although the subscapularis tendon attachment is not a sum of 4 facet squares, we have represented it as a sum of squares to make understanding tear patterns easier. The red area depicts torn or detached footprint. Note that the tear pattern is usually diagonal, because subscapularis tears occur medially and inferiorly first. The term lateral hood is used because in the arthroscopic view, the subscapularis tendon footprint is easily opened, but the most lateral tissue is usually intact, meaning it is not a full-thickness tear of the subscapularis tendon. (a) Type I tear, (b) type IIA tear, (c) type IIB tear, (d) type III tear, (e) type IV tear and (f) type V tear.

hood is the term used for the subscapularis tendon remaining on the most lateral insertion, since most of the subscapularis upper third tear starts from the articular side or intratendinous tear (CIST, Concealed Intratendinous Subscapularis tendon Tear). This remaining tissue means the tear is incomplete, but if the lateral hood is disrupted this will cause a complete tear; equivalent to a full-thickness tear of the supraspinatus tendon.

Currently, there is no universally accepted guide to differentiate tear patterns of partial upper portion tears of the subscapularis. Finding the first facet of the subscapularis footprint and determining the amount of detachment of this facet will allow surgeons to estimate the extent of subscapularis footprint involvement. If you can see nearly the entire opening of this first facet during arthroscopy then you are dealing with one-third involvement of the entire subscapularis footprint attachment. Once you identify this first facet you can further subdivide it to distinguish between a partial versus complete (full-thickness) one-third tear and establish a treatment plan.

Our treatment principles for subscapularis tendon tear were based on Yoo and Rhee's Subscapularis tendon tear classification according to facet exposure and lateral band (Figure 3):

1. Type I: fraying or longitudinal split of subscapularis leading edge tendon.
2. Type IIA: less than 50% subscapularis tendon detachment to first facet.

3. Type IIB: greater than 50% detachment without complete disruption of lateral hood, which is approximately a one-quarter to one-third tear of the entire subscapularis tendon's superior-inferior length.
4. Type III: entire first facet with complete-thickness tear (lateral hood disruption or tear)
5. Type IV: first and second facets exposed, with tendon having a much more medial retraction (approximately two-thirds tear of the entire subscapularis superior-inferior length; the entire tendinous portion).
6. Type V: complete subscapularis tendon tear involving the muscular portion. The most common type of tear was Type II (about 50 % of entire distribution) involving the first facet¹³.

HOW TO EVALUATE SUBSCAPULARIS TENDON TEAR

Subscapularis tendon tears are difficult to diagnose by physical examination. Patients report vague anterior shoulder pain. Pain location and radiation is not reliable for the diagnosis of subscapularis injury. We can observe decreased internal rotation strength, increased passive external rotation and positive findings in subscapularis-specific physical examinations such as lift-off test, belly press test and bear hug test in patients with definite subscapularis tendon tears. However, most subscapularis tendon tears

are partial. Sensitivity and specificity of several physical examinations are markedly variable if the tear is partial. Although several techniques have been described to evaluate subscapularis tendon tear, clinical evaluation of subscapularis injuries remains difficult for partial upper third (or less) tear.

Ultrasound examination is a useful diagnostic tool to detect rotator cuff tears. However, the sensitivity and specificity of ultrasonography in detecting of subscapularis tendon tear is lower than that of supraspinatus and infraspinatus¹⁸. Sensitivity is particularly decreased in the axial view because articular side partial tears are easily masked by external rotation.

MRI examination is widely accepted as the imaging modality of choice to detect of rotator cuff tears. However, just like ultrasonography, the detection rate of subscapularis tendon tear is much lower. In coronal images, the subscapularis tendon and muscle lie in the same anatomic plane, so subtle partial tears or even complete tears are difficult to assess. So, axial-view images are often accepted as most important in the evaluation of subscapularis tendon. While, it is true that high-contrast axial plane images visualise the anatomic course of the subscapularis tendon and its insertion on to the lesser tuberosity, specificity for subscapularis tendon abnormalities with sagittal oblique images was higher than those obtained with axial images, although comparable sensitivities were found¹².

acute trauma, overuse or improper technique during the overhead phases of throwing, swinging or swimming could put athletes at risk of subscapularis tendon injury

In our recent correlation study of MRI and arthroscopic findings, we found that sagittal oblique images were better at detecting partial one-third tears than axial images¹⁹. However, both axial and sagittal oblique images can only detect upper third tears in 50% of cases. Nonetheless atrophy and fatty infiltration may be helpful for correct diagnosis by MRI.

Arthroscopic examination is another valuable tool that can be used to accurately detect subscapularis tendon tear. This examination is particularly useful in most cases in which there is an articular-side subscapularis tendon tear, especially if one uses a 70° scope, with slight internal rotation of the humerus and elevation away from the glenoid. Despite this, in some tight joints it is difficult to see the footprint exposure even with a 70° scope.

On the other hand, lesions in the cranial part of the subscapularis tendon are difficult to diagnose clinically and may even be missed during surgery if they are not specifically sought¹⁹. During arthroscopic examination, the articular surface of the capsule may be visually intact in patients with complete subscapularis tendon tears. We recommend routine exploration of structures around the rotator interval in patients with supraspinatus tear during surgery. In most cases, type III and IV tears have a capsule from 3 o'clock (right shoulder) which masks the extent of subscapularis tendon tear. On probing, the finding of an unusually soft and elastic capsule may lead to the correct diagnosis³.

WHEN SHOULD WE OPERATE FOR SUBSCAPULARIS TENDON TEAR?

The management of subscapularis tears is aimed at restoring the integral role of this muscle in the shoulder.

As previously mentioned, operative management should be cautiously determined because it is difficult for elite athletes to regain preoperative levels of performance in elite athletes.

Our principle of subscapularis tendon tear in athletes is; if a small partial tear (up to type IIB) is asymptomatic and incidentally found, observation could be possible. However, if the tear is symptomatic and it influences the performance of the athletes, we recommend that any Type IIB

or more severe tear should be managed through arthroscopic repair. For non-athletic and older patients we are still investigating whether to operate all type IIB tears. We strongly recommend repairing all type III and IV tears if possible, however type IIB tears with intact lateral hood may be more stable than previously thought. The question 'why not repair all rotator cuff tears including subscapularis? They were not torn to start with?' might have some logical sense. However, some patients have full-thickness superior tears (well-contained tears or cuffs) and minimal symptoms and dysfunctions, which makes this line of reasoning more contentious. Further research on this issue is required.

Arthroscopic repair can be safely and successfully performed. It requires tendon mobilisation to reach the lesser tuberosity. If the tendon is not mobilised sufficiently, its footprint can be medialised about 5 to 7mm. Arthroscopic results are encouraging in terms of recovery to a general level of activity. At intermediate follow-up, improvement in functional scores and patient satisfaction has been reported. Our surgical results on isolated and combined subscapularis tendon tear and repair are promising. However, physical examinations and strength tests do not seem to show

full recovery. All reported outcomes are comparable to that of open repair, with a very low complication rate and no major intraoperative complications. However, the successful return-rate to preoperative level of performance in elite athletes was low^{4,20}.

OUR REPAIR TECHNIQUES FOR SUBSCAPULARIS TENDON TEAR

With the patient positioned in lateral decubitus, the operative arm was placed in a position of 20° to 30° of abduction and 20° of forward flexion (Star Sleeve Traction System, Arthrex Inc., Naples FL). A diagnostic arthroscopy was performed with a 30° arthroscope viewing through a standard posterior portal. The biceps was frequently dislocated from the bicipital groove affecting the subscapularis tendon tear. Either tenotomy or tenodesis of the biceps could be performed depending on age, gender and functional requirements of the patient. When visualised during arthroscopy, the subscapularis tendon frequently loses its taught leading tendon. Firm tendinous appearance could be seen in normal tendons. The torn portion is medially or downward-migrated (lateral decubitus), showing some amount of sagging. This finding is typical in subscapularis tendon tears with detachment of more than half

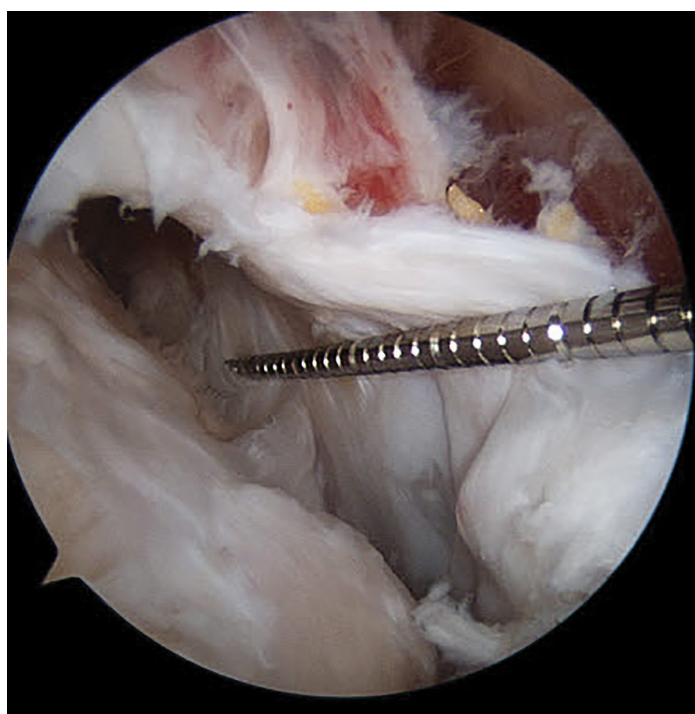


Figure 4: The size of the subscapularis tendon tear is evaluated at bursal side using a calibrated ruler.

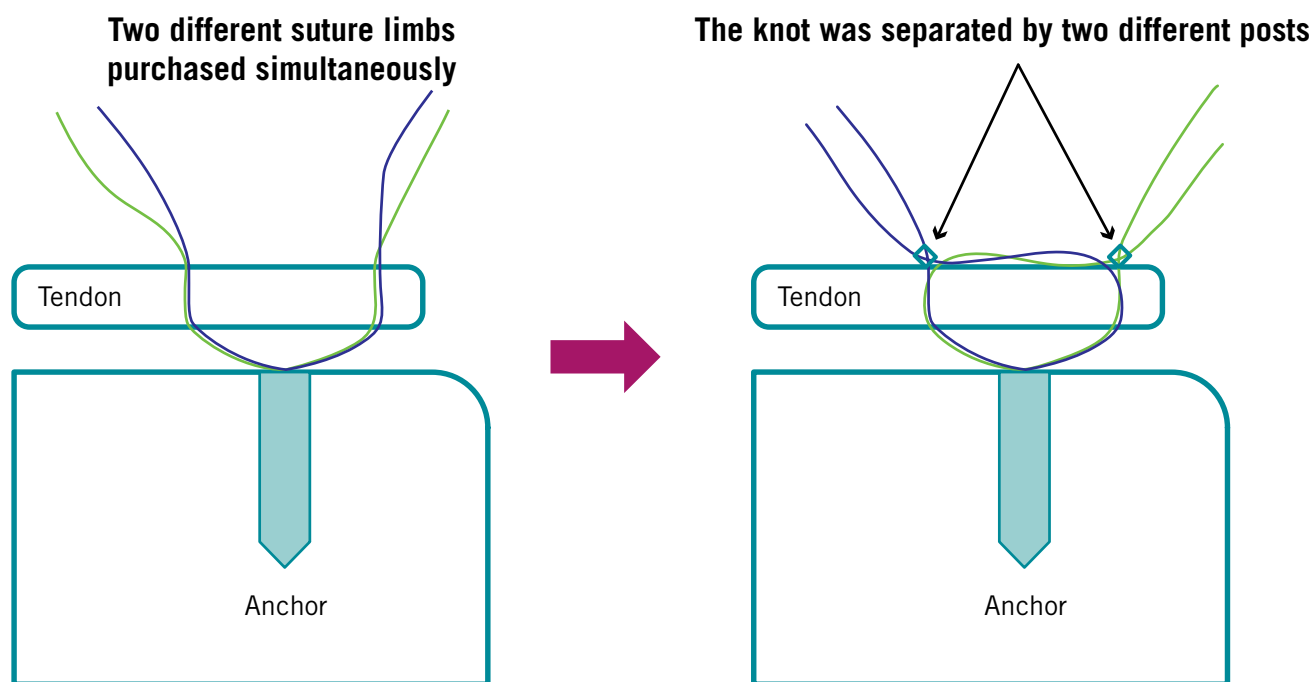


Figure 5: Both limbs were tied with non-sliding knots (one post in a superior position, the other in an inferior position).

of the first facet. We used a 70° scope to better view the subscapularis footprint (so-called aerial view of the footprint). To improve visualisation, the arm was placed in 30° abduction and 30° internal rotation to view the subscapularis insertion. The size of the subscapularis tendon tear was more thoroughly evaluated using a probe and calibrated ruler at a 1 mm scale. Then, we moved to the bursal side of the rotator cuff changing back to a 30° scope (Figure 4). The usual subacromial portals were made via posterior, anterior, anterolateral and posterolateral portals. With the scope in the lateral portal, a calibrated probe was introduced from the anterior portal to measure the dimensions of the subscapularis tear from lateral to medial. After that, the probe was introduced from the anterior or anterolateral portal with the scope in the lateral or posterolateral portal to measure the dimension of the tear in superior to inferior direction. The extent of the tear was estimated by comparing the first facet dimension, known to be approximately 13 mm anterior-posterior and 13 mm superior-inferior. Once the decision to repair arthroscopically was made, the footprint was prepared using a shaver,

burr and microfracturing. The torn tendon edge was lightly shaved to remove poor tissue and enhance bleeding tendency after repair. The coracohumeral ligament and adhesions to anterosuperior margins of the subscapularis tendon were released to allow better mobilisation of the torn retracted tendon to its footprint without tension. The release of soft tissue was performed at the coracoid base, taking caution not to completely sever the rotator interval tissue and coracohumeral/superior-glenohumeral ligaments. Afterwards, the medial anchor and double-loaded suture anchor Healix (DePuy Mitek, Raynham MA) were placed most inferiorly and medially to the first facet. For this medial and inferior anchor placement, we had to make an additional anchor portal medial to anterior portal. It is usually located just lateral to the common tendon. This can be identified with a spinal needle, with the needle perpendicular to the subscapularis footprint (first facet). The double-loaded suture anchor was inserted in the same direction as the spinal needle left for guidance. After proper anchor insertion, a suture hook (Linvatec, Largo, FL) was preloaded with No. 0 PDS (Ethicon) introduced through the anterior

or anterolateral portal for suturing. The suture hook penetrates the full thickness of the subscapularis tendon from bursal side towards articular side 1 or 2 mm below the superior margin of the tear and 12 to 13 mm medial to the lateral margin of the tear. PDS was used to relay both limbs of the sutures simultaneously. The same step was repeated for shuttling the remaining two suture limbs of the anchor approximately 5 mm to ~10 mm inferior to the first stitch. Both limbs were tied with non-sliding knots (one post at the superior, the other at the inferior position). (Figure 5) The lateral row anchors were placed on the bicipital groove. One was on the most superior side. The other was 1 to 2 cm below the first anchor on the groove. As in the supraspinatus suture bridge, the same limbs from each tied knot were gathered to place one superiorly and the other inferiorly. Then, the torn subscapularis tendon was repaired with full coverage of footprint at the bursal side. Postoperatively, patients were immobilised with a sling for 4 to 6 weeks depending on combined supra/infraspinatus tendon tears. After this, passive shoulder range of motion exercise was started. At 12 weeks postoperatively, strengthening exercises were started.



Pain location and radiation is not reliable for the diagnosis of subscapularis injury



SUMMARY

The prevalence of subscapularis tendon tears is reported to be much higher than what has been reported, even up to 50% over the age of 50 years old. The first facet of the subscapularis tendon insertion seems approximate to one-third of the entire footprint. This landmark would be a guideline for arthroscopic surgeons. Complete or full-thickness tears of this first facet are type III tears, which seem to warrant surgical repair. Further research is required to determine the need for surgical repair of type II tears, especially in athletes.

References

1. Ticker JB, Burkhart SS. Why repair the subscapularis? A logical rationale. *Arthroscopy* 2011; 27:1123-1128.
2. Morag Y, Jamadar DA, Miller B, Dong Q, Jacobson JA. The subscapularis: anatomy, injury, and imaging. *Skeletal Radiol* 2011; 40:255-269.
3. Gerber C, Krushell RJ. Isolated rupture of the tendon of the subscapularis muscle. Clinical features in 16 cases. *J Bone Joint Surg Br* 1991; 73:389-394.
4. Reynolds SB, Dugas JR, Cain EL, McMichael CS, Andrews JR. Debridement of small partial-thickness rotator cuff tears in elite overhead throwers. *Clin Orthop Relat Res* 2008; 466:614-621.
5. Arai R, Sugaya H, Mochizuki T, Nimura A, Moriishi J, Akita K. Subscapularis

tendon tear: an anatomic and clinical investigation. *Arthroscopy* 2008; 24:997-1004.

6. Curtis AS, Burbank KM, Tierney JJ, Scheller AD, Curran AR. The insertional footprint of the rotator cuff: an anatomic study. *Arthroscopy* 2006; 22:609.e1.
7. Ide J, Tokiyoshi A, Hirose J, Mizuta H. An anatomic study of the subscapularis insertion to the humerus: the subscapularis footprint. *Arthroscop.* 2008; 24:749-753.
8. D'Addesi LL, Anbari A, Reish MW, Brahmabhatt S, Kelly JD. The subscapularis footprint: an anatomic study of the subscapularis tendon insertion. *Arthroscopy* 2006; 22:937-940.
9. Richards DP, Burkhart SS, Tehrany AM, Wirth MA. The subscapularis footprint: an anatomic description of its insertion site. *Arthroscopy* 2007; 23:251-254.
10. Dugas JR, Campbell DA, Warren RF, Robie BH, Millett PJ. Anatomy and dimensions of rotator cuff insertions. *J Shoulder Elbow Surg* 2002; 11:498-503.
11. Lafosse L, Jost B, Reiland Y, Audebert S, Toussaint B, Gobezie R. Structural integrity and clinical outcomes after arthroscopic repair of isolated subscapularis tears. *J Bone Joint Surg Am* 2007; 89:1184-1193.
12. Pfirrmann CW, Zanetti M, Weishaupt D, Gerber C, Hodler J. Subscapularis tendon tears: detection and grading at MR arthrography. *Radiology* 1999; 213:709-714.
13. Yoo JC, Rhee YG, Shin SJ, Park YB, McGarry MH, Jun BJ et al. Subscapularis tendon tear classification based on 3-dimensional anatomic footprint: a cadaveric and prospective clinical observational study. *Arthroscopy* 2015; 31:19-28.
14. Barth JR, Burkhart SS, De Beer JF. The bear-hug test: a new and sensitive test for diagnosing a subscapularis tear. *Arthroscopy* 2006; 22:1076-1084.
15. Kronberg M, Nemeth G, Broström LA. Muscle activity and coordination in the normal shoulder. An electromyographic study. *Clin Orthop Relat Res* 1990:76-85.
16. Reddy AS, Mohr KJ, Pink MM, Jobe FW. Electromyographic analysis of the deltoid and rotator cuff muscles in persons with subacromial impingement. *J Shoulder Elbow Surg* 2000; 9:519-523.
17. Omi R, Sano H, Ohnuma M, Kishimoto KN, Watanuki S, Tashiro M et al. Function of the shoulder muscles during arm elevation: an assessment using positron emission tomography. *J Anat* 2010; 216:643-649.
18. Teefey SA, Middleton WD, Payne WT, Yamaguchi K. Detection and measurement of rotator cuff tears with sonography: analysis of diagnostic errors. *AJR Am J Roentgenol* 2005; 184:1768-1773.
19. Walch G, Nove-Josserand L, Levigne C, Renaud E. Tears of the supraspinatus tendon associated with "hidden" lesions of the rotator interval. *J Shoulder Elbow Surg* 1994; 3:353-360.
20. Payne LZ, Altchek DW, Craig EV, Warren RF. Arthroscopic treatment of partial rotator cuff tears in young athletes. A preliminary report. *Am J Sports Med* 1997; 25:299-305.

Yong Bok Park M.D.
Orthopaedic Surgeon

Jae Chul Yoo M.D.
Orthopaedic Surgeon

Department of Orthopaedic Surgery
Samsung Medical Centre
Sungkyunkwan University School of Medicine
Seoul, Korea

Contact: shoulderyoo@gmail.com