

This paper was originally published in Volume 3, Targeted Topic 3, Sports Medicine in Handball, 2014, p172-179.

ACUTE FINGER INJURIES IN HANDBALL

– Written by Gregoire Chick, Switzerland and Qatar

In handball, the hand acts as an instrument to launch or receive the ball. The fingers may be caught along the trajectory of the ball or during falls or contact with other players and injured.

The thumb and long fingers are considered differently. Thumb joint lesions cause instability and secondary osteoarthritis; stability should be favoured over mobility to ensure opposition. For long fingers, the goal is always the earliest possible mobility in order to limit the risk of permanent stiffness.

FEATURES SPECIFIC TO HANDBALL

A handball ball is small (58 to 60 cm in circumference for men, 54 to 56 cm for women) and fits perfectly in the palm of the hand. The fingers are spread, the thumb stabilises and the 5th finger locks¹ (Figure 1). The leather gives players a strong hold on the ball while also enabling smooth contact and touch. The defenders are entitled to block

the ball by making a wall and lifting their arms up. The throw consists of a shoulder movement towards the target, with a flexion of the wrist at the end. The fingers should be pointing at the target (Figure 2).

TYPES OF FINGER LESIONS AND EPIDEMIOLOGY

Hand injuries account for 9% of all injuries in athletes², probably because the hand serves as a form of protection and often receives the initial impact³. The reported frequency of hand trauma is 30% of all trauma for handball compared to 19% and 23% for basketball and volleyball, respectively⁴. The fingers are affected three out of four times⁵.

Sprains are common, especially at the proximal interphalangeal (PIP) joints of long fingers. Of volar plate lesions, 22% occur in handball⁶. Dislocations are rare and sometimes affect both PIP and distal interphalangeal (DIP) joints. Recent injuries

ABBREVIATIONS	
PIP	proximal interphalangeal
DIP	distal interphalangeal
MCP	metacarpophalangeal
UCL	ulnar collateral ligament
RCL	radial collateral ligament

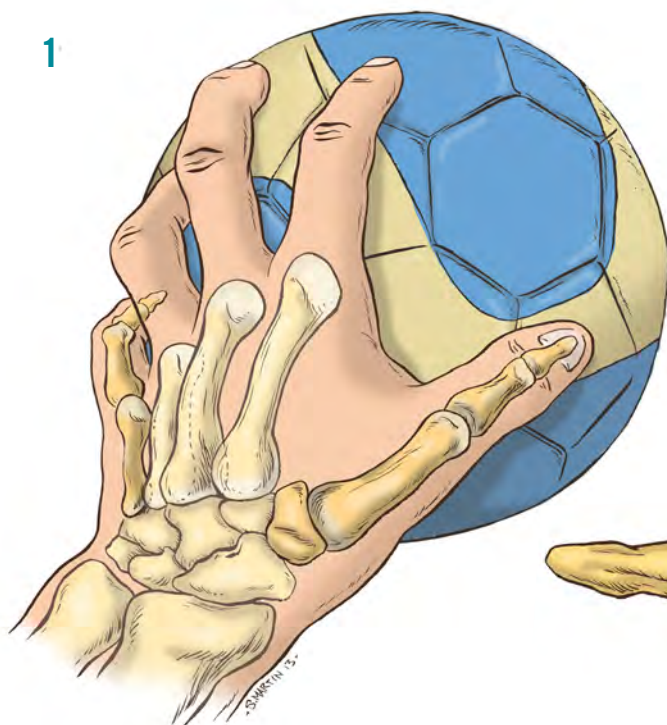
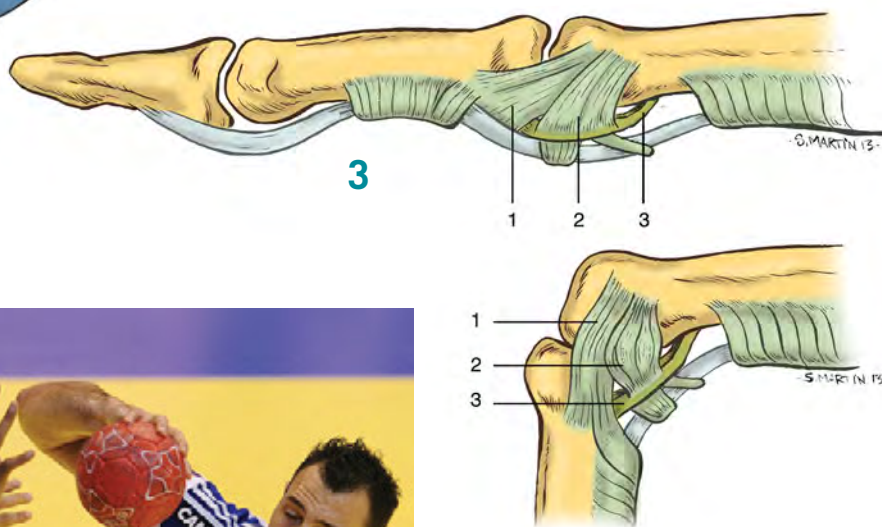


Figure 1: Holding the handball: the thumb and little finger have major roles.

Figure 2: French captain Jerome Fernandez controls the ball during the Men's EHF Euro 2012 Handball Championship match between France and Iceland.

Figure 3: Ligaments of the proximal interphalangeal joint. 1=main collateral ligament, 2=accessory collateral ligament, 3=volar plate.



of the metacarpophalangeal (MCP) joint of the thumb are common, unlike those of long finger MCP joints that are often unrecognised and undertreated. Receiving the ball in the axis of the finger can cause a closed extensor lesion, most commonly a mallet finger injury.

SPRAINS AND DISLOCATIONS OF LONG FINGERS

Very common in handball, finger sprains cause persistent pain often with stiffness, leaving joints voluminous due to capsuloligamentous scarring, which is poorly understood and accepted by the

athlete⁶. Sprains represent incomplete lesions of the capsular and ligament layers without loss of joint congruence, while dislocations involve complete breakdown in the joint structure.

Relevant anatomy

Unlike MCP joints, collateral ligaments of PIP and DIP joints are stretched in extension and relaxed in flexion (Figure 3).

Mechanism

The vast majority of lesions are benign sprains resulting from direct axial impact by a ball or contact during the game. According

to the direction of the forces and the energy expended, one or more structures can be injured to varying degrees:

- Collateral ligaments.
- Volar plate (Figure 4).
- Central slip of the extensor mechanism.

At least two must be completely ruptured to cause dislocation. Of PIP and DIP dislocations, 90% are dorsal and often reduced immediately on the handball court (Figure 5).

Clinically

After the trauma, the pain is the main feature associated with local swelling in these athletes. There may be lateral laxity (tested for in extension) in case of complete rupture of the collateral ligament. Even a partial rupture will cause scarring and swelling that may persist for several months associated with painful loss of flexion. This is commonly reason for secondary presentations. Dislocation results in functional disability and finger deformity.

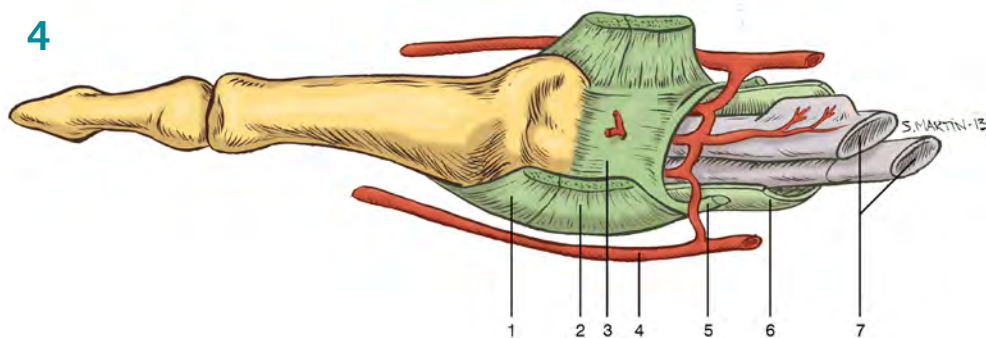


Figure 4: Palmar plate. 1=main collateral ligament, 2=accessory collateral ligament, 3=volar plate, 4=collateral artery, 5=check-rains, 6=A 3 pulley, 7=flexor tendons.

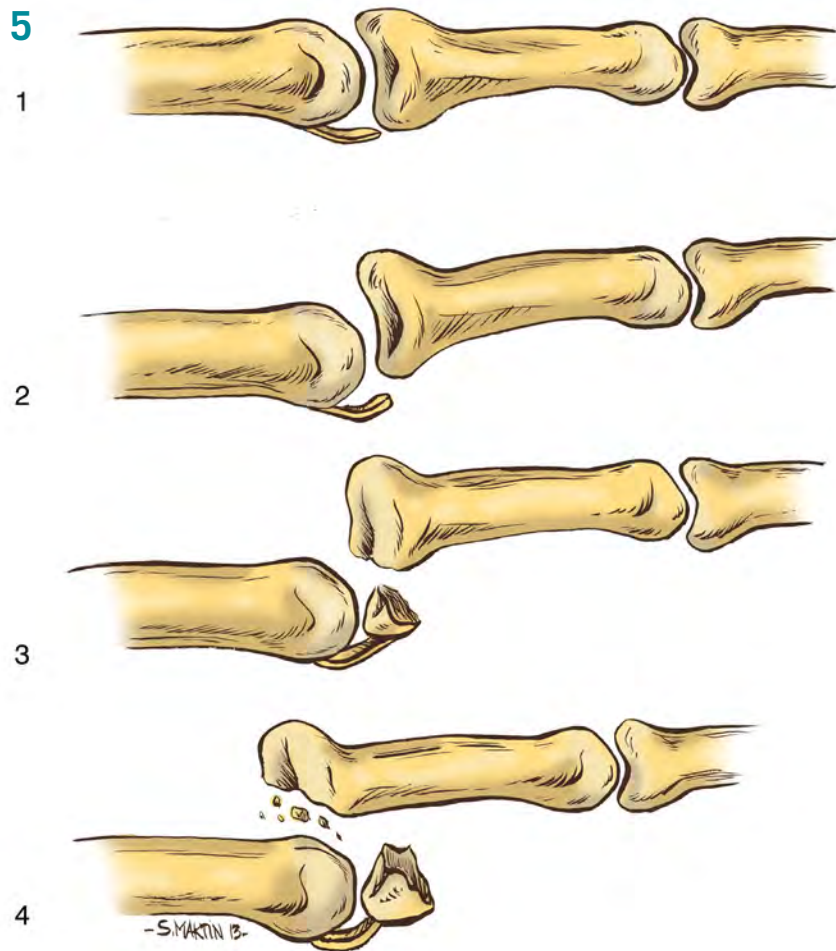
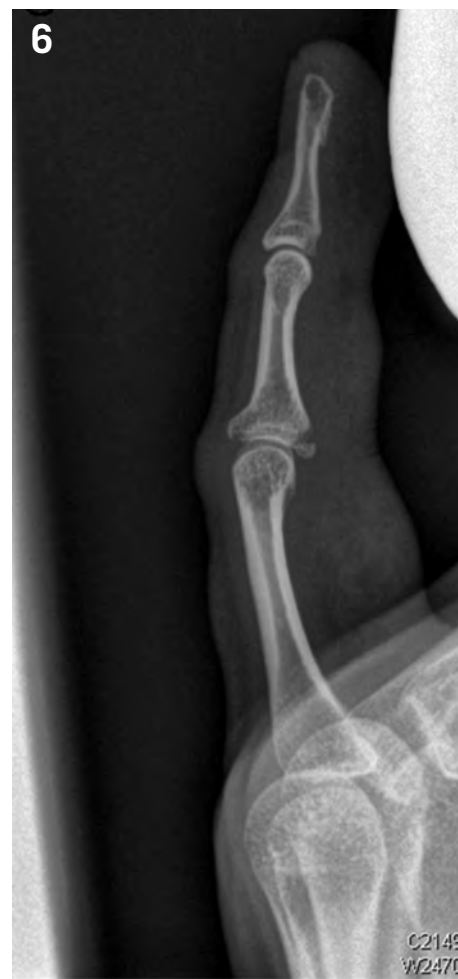

Figure 5: The proximal interphalangeal joint is the most common site of ligament injuries of the hand, ranging from simple sprains (jammed finger) to the very challenging proximal interphalangeal fracture-dislocation.

Figure 6: Palmar plate avulsion left little finger (strict lateral view).



Investigations

Plain anteroposterior (AP) and lateral X-rays of the finger are often sufficient. We look for a palmar or lateral avulsion at the base of P1, a dislocation or subluxation (Figure 6).

Ultrasound may show the volar plate and collateral ligaments; it is especially useful to detect injury to the radial collateral ligament of the index. A complete or high-grade partial tear may lead to persistent pain or instability due to the stresses on this joint during the pinch mechanism. US or MRI can confirm the presence of this injury with consideration of early surgical repair⁷.

Treatment

The treatment is almost always conservative. The aim is to regain digital mobility as quickly as possible. The potential for spontaneous recovery is high; collateral ligaments often remain in place even after dislocation. The main risk is stiffness, especially in flexion, due to the tendency of the palmar plate to retract. It is therefore particularly important to immobilise the PIP in extension. Immobilisation must be short, maximum 7 to 10 days, and may continue at night for 3 weeks. Buddy taping to the neighbouring finger takes the relay and allows early mobilisation.

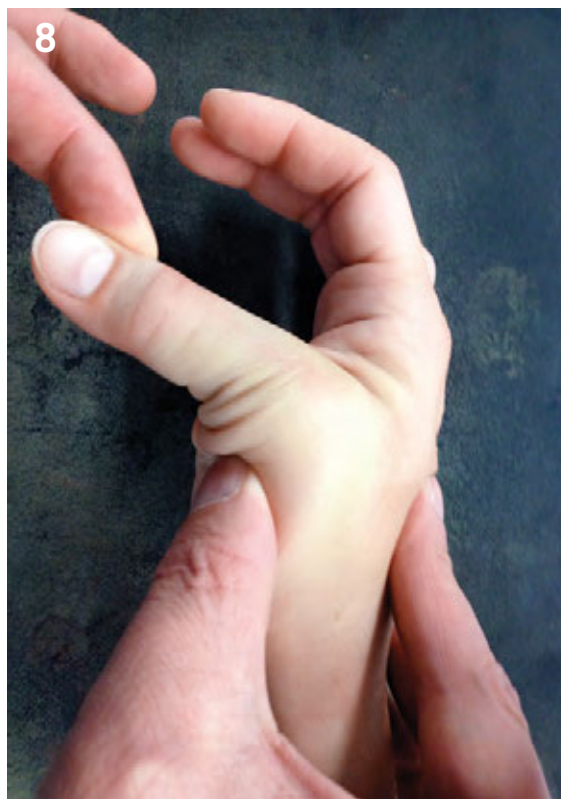
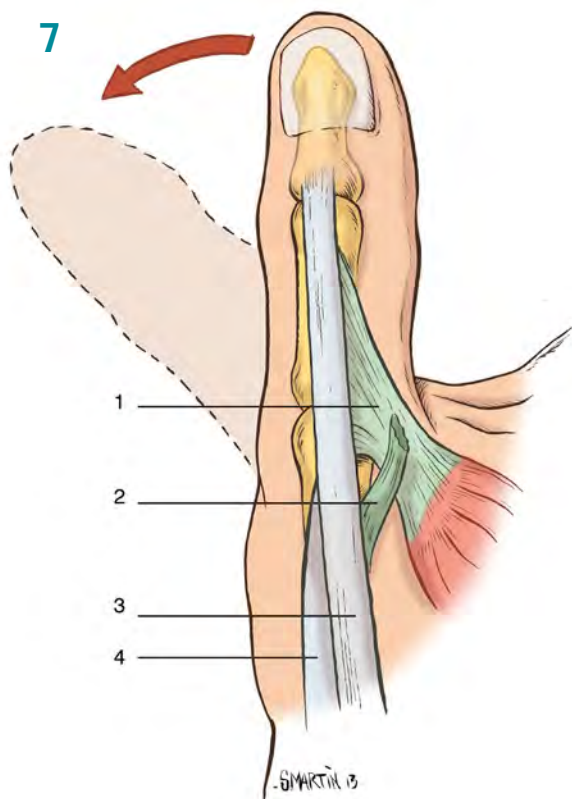


Figure 7: Stener lesion. This occurs when the aponeurosis of the adductor pollicis muscle becomes interposed between the ruptured ulnar collateral ligament of the thumb and its site of insertion at the base of the proximal phalanx.

Figure 8: Valgus stress test is the main manual manoeuvre for assessing the grade of ulnar collateral ligament tear.

A dislocation should be reduced without force under local anaesthesia. Ligaments and the extensor apparatus should be tested. Follow-up is the same.

Return to sport is possible after 3 to 6 weeks of treatment depending on the severity of the sprain.

The indications of surgery are rare:

- Irreducible dislocation with soft tissue (volar plate) interposition especially after anterior dislocation.
- Major instability after reduction.
- Open dislocation.
- Associated neighbouring lesions (fracture, tendon injury)⁸.

Complications

- Flexion deformity after inappropriate and prolonged immobilisation in flexion.
- Boutonniere deformity.
- Chronic instability after repeated injuries.
- Secondary osteoarthritis (rare).

Key points

- Sprains are very common in young handball players (especially PIPs) and benign if properly treated initially with adequate position and duration of immobilisation.

- Stability of the interphalangeal collateral ligaments must be tested in extension.
- Conservative treatment is the standard in most cases.

SPRAINS OF THE MCP THUMB

The thumb collateral ligaments at the MCP joint are important to the elite athlete for precision grip and pinch. Injuries of these ligaments can result in pain and instability.

Mechanism and pathophysiology

Lesions of the thumb MCP are common and vary in severity, ranging from mild sprain to dislocation. Due to its position in grip, the ulnar collateral ligament (UCL) is much more frequently injured (86% of cases⁶) than the radial collateral ligament (RCL). The potential for spontaneous healing of the UCL is also lower due to the risk of avulsion of the ligament proximal and superficial to the adductor aponeurosis (Stener lesion⁹) (Figure 7).

Disruption of the UCL of the first MCP joint arises as a result of an acute radial or valgus stress on the thumb. Injury can occur in the form of an avulsion fracture, an isolated ligament tear or combined fracture and ligament rupture. Repeated injuries

('gamekeeper's thumb') or an untreated rupture can cause chronic instability of the UCL.

Epidemiology

Handball is involved in 15% of cases of UCL-related injuries vs 75% in skiing⁶. Handball is also responsible for 40% of RCL lesions.

Clinical

There is diffuse swelling of the MCP which is more pronounced over the injured ligament. It is tender on palpation. Lateral stability is tested in 20 to 30° MCP flexion to cancel the stabilising effect of the volar plate in extension (Figure 8). With some caution, this manoeuvre can be done without using a local anaesthetic. The examination must be comparative, especially when the patient has constitutional ligament laxity. Laxity greater than 30° generally signifies rupture.

Investigations

AP and lateral views must be taken before stability testing to avoid displacing a fracture fragment and worsening a benign lesion (Figure 9).

X-rays can show:

- Lateral or palmar avulsion or fracture base P1.

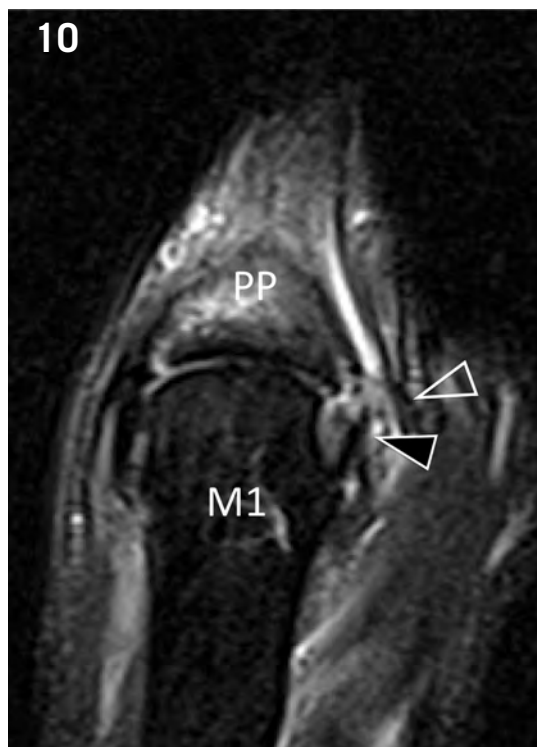
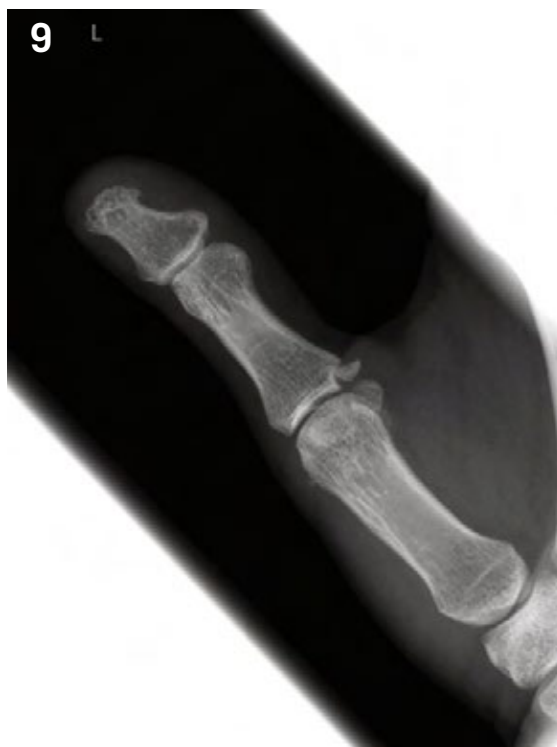

Figure 9: Anteroposterior view of the thumb demonstrates avulsion fracture from the ulnar base of the proximal phalanx.

Figure 10: Complete tear of the ulnar collateral ligament of MCP joint of the thumb. MRI coronal T2-weighted MR images with fat saturation. MRI shows a complete tear of the distal part of the ligament (black arrowhead). The proximal stump is retracted proximally at the level of the metacarpal (M1) head. Note local oedema (open arrowhead). PP=proximal phalanx. (Reproduced with permission from Dr Emad Almusa, Aspetar).

- Subluxation or lateral deviation due to UCL or UCR lesion.

Stress radiographs may demonstrate instability and widening of the ulnar aspect of the first MCP articulation, with greater than 30° difference between the stress and neutral positions.

Ultrasound can accurately demonstrate a Stener lesion, interposition of the aponeurosis of the adductor brevis muscle between the torn ligament ends. However, US does not replace clinical examination. MRI can confirm complete or incomplete ligament injury (Figure 10). 3D reformatted and volume-rendered CT images allow 3D visualisation of the osseous structures, which can be useful for surgical planning.

Classification

The general classification of ligament injury divides them all into three types¹¹:

- **Grade I:** Also known as a sprain and represents a small, incomplete tear. Tenderness is present over the site of injury but there is no laxity on stress examination.
- **Grade II:** A larger but still incomplete tear with greater pain and swelling over the injured side. Asymmetrical laxity of the joint is present on examination but a firm end point is present.
- **Grade III:** Represents a complete tear of the ligament. There is marked laxity of the joint with no firm end point.

Treatment

Conservative treatment¹¹

- In **grade I** ligament injury, 3 weeks immobilisation by thumb spica thermoplastic splint is indicated (Figure 11). After this period, no more fixation is required and rehabilitation is started to restore movement. Handball activity is allowed 5 weeks after ligament sprain accident.
- In **grade II** injury, 4 weeks of immobilisation with a short-arm thumb spica cast is required. Movement exercises in flexion/extension are started after 4 weeks to prevent MCP joint stiffness, but an additional 2 weeks of immobilisation in a thumb splint is necessary. A strengthening protocol is started 6 weeks after injury. Return to active sport is allowed 10 weeks after trauma if there is no pain and severe limitation of movement, with protective taping, if necessary.

Most sprains heal favourably, but the lesion may remain tender for several months, especially on gripping.

Surgical treatment

Intervention is necessary when there is **grade III** instability or a displaced bone fragment; the avulsed ligament is usually re-inserted at the proximal phalanx using a mini anchor, or rarely using direct suture or screw fixation. Postoperatively, the thumb

is protected in a thermoplastic splint for 4 weeks followed by night splinting for 2 weeks. Unrestricted return to sports is allowed 3 months after surgery⁹.

Complications

- Chronic MCP joint instability due to UCL, RCL or volar plate in case of ligament injury of more than 6 to 8 weeks.
- MCP joint stiffness.
- MCP joint osteoarthritis.
- Injury of dorsal sensory branch (requires surgery).

Key points

- UCL lesions are most frequent, however RCL lesions must not be neglected.
- Clinical examination is key in diagnosing instability.
- Surgery is indicated for unstable lesions with complete rupture, conservative treatment for others.
- Sensory branches of the radial nerve must be protected during incision.

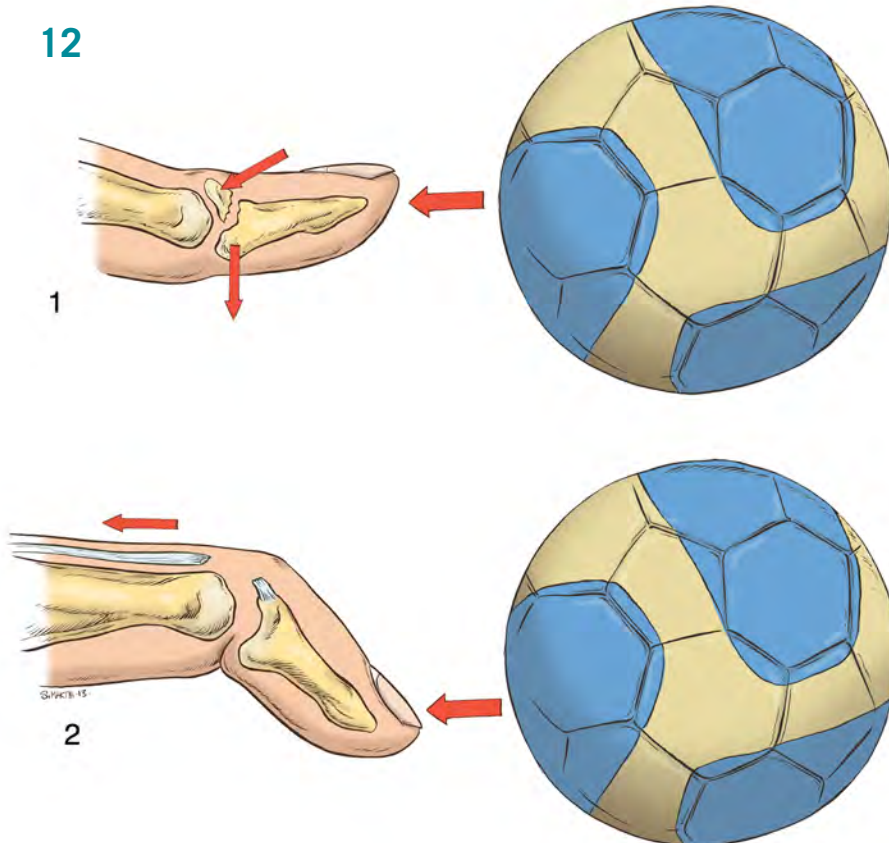
CLOSED MALLET FINGER

The extensor apparatus is complex and delicate. In balance with the flexor apparatus, it is crucial in all acts of manipulation and grasping. The extensor tendons are thin and cover a broad surface which makes them vulnerable to injury and susceptible to the re-injury.

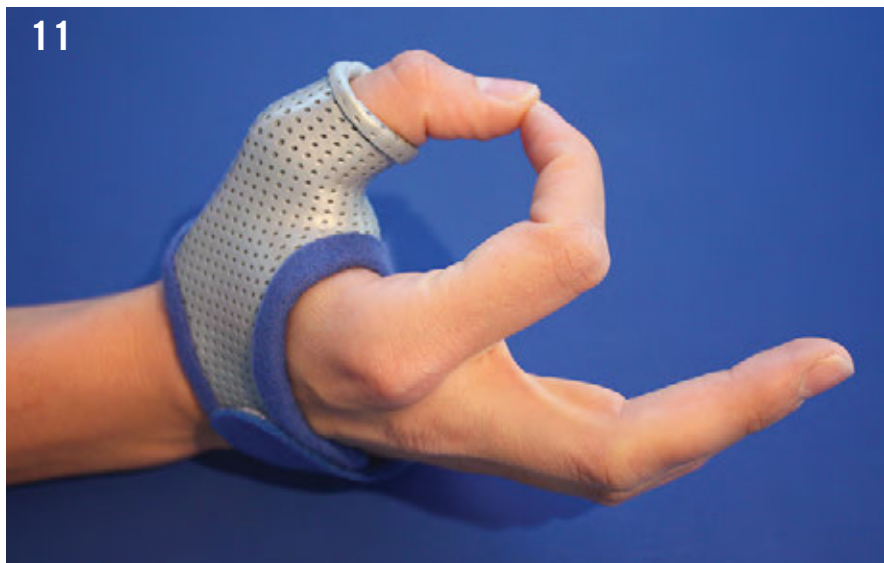

Figure 11: Protective splint for ulnar collateral avulsion. Fixation of the interphalangeal joint of the thumb is contraindicated in all types of ligament tear and healing period. Its movement prevents scarring between the extensor tendon and dorsal metacarpophalangeal joint capsule with consequent stiffness.

Figure 12: The two types of mallet finger and their mechanism.



Following closed trauma, the site of the extensor lesion will determine the type of deformity: a central tendon lesion on the back of the PIP results in boutonniere deformity, while rupture at the distal extensor insertion causes a mallet finger (or baseball finger) particularly common in handball.

Epidemiology

Most commonly seen are closed mallet finger injuries which are known as a Type

I injury. Mallet finger is more common in males, with significant trauma in younger males and minor traumas in older females. Most injuries (66%) occur in the dominant hand with the most common involvement being of the last three digits and is typically limited to only one finger.

Mechanism and pathophysiology

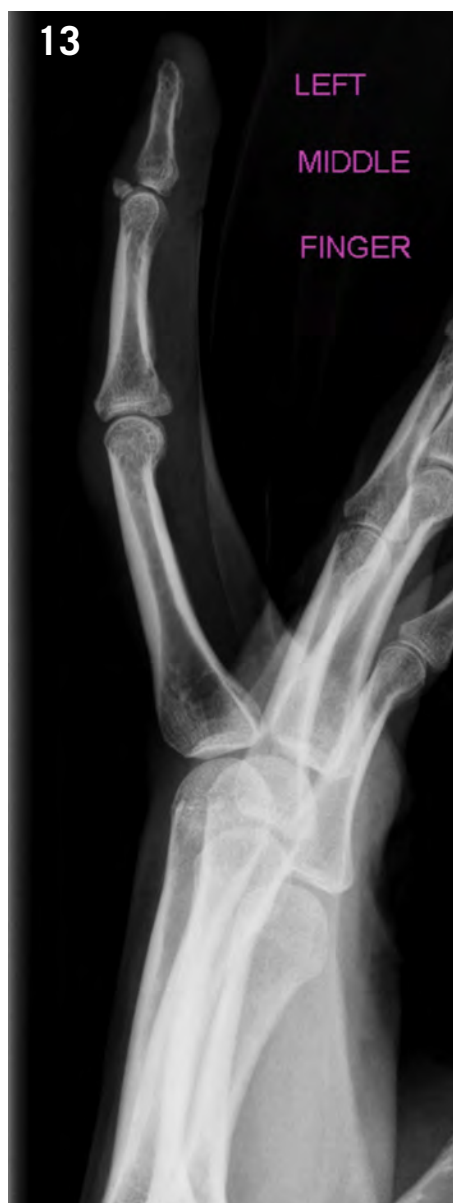In most cases, mallet finger results from avulsion (or less commonly section) of the extensor insertion at the base of the distal

phalanx of the fingers or thumb (rare). The bony mallet is a \pm displaced fracture at the extensor insertion at the base of P3. Extensor avulsion at the base of the distal phalanx usually occurs during a forced extension of DIP in flexion¹³. A fracture dislocation usually occurs during axial trauma, with DIP extension or hyperextension, with simultaneous tension of flexors and extensors (Figure 12). Retraction of the extensor apparatus is less marked than that of flexor tendons but is nevertheless significant.

Clinical

The players often present late, several days later, having expected spontaneous recovery. The deformity is usually immediate, but can be delayed. The distal phalanx drops with spontaneous flexion of the DIP, loss of active extension with functional disability (hooking). Sometimes there is hyperextension of the PIP by an imbalance between traction on the central and lateral tendons. There is little or no pain. There may be a small dorsal localised swelling or bruising if there is an associated fracture.

Dislocation results in functional disability and finger deformity



Investigations

AP and strict lateral views of the DIP show the presence, size and displacement of a bone fragment and the presence of a palmar subluxation of the distal phalanx or osteoarthritis (Figure 13).

Classification

Wilson¹⁴ distinguishes four types of lesions (Figure 14):

1. **Type 1:** Subcutaneous extensor tendon rupture a few millimetres proximal to its insertion, causes a DIP extension deficit which may vary depending on the extension of the lesion laterally to the oblique retinacular ligament.
2. **Type 2:** Tendon avulsion flush with its insertion on P3 ± with a very small bony fragment not involving the articular surface.
3. **Type 3:** Avulsion fracture – bony fragment not more than 1/3 of the articular surface.
4. **Type 4:** Fracture subluxation with a bony fragment at the dorsal base P3 greater than 1/3 of the articular surface, resulting in palmar dislocation of the DIP due to the action of the FDP.

Treatment

Conservative treatment

Closed fractures (Type 1, 2 and 3) are treated conservatively. Many immobilisation methods exist such as stack splints or glued splints to keep the DIP joint in neutral position or slight extension. I

prefer a thermoplastic slab with a thin protective cloth to spare the skin, keep the pulp free and immobilise the PIP joint (Figure 15).

In the absence of bony lesion (Type 1 and 2), the recommended period of immobilisation is 8 continuous weeks with an additional 4 weeks of night splinting. In a bony fragment, less than 1/3 of the articular surface and without subluxation of the DIP joint (Type 3), the downtime can be shortened to 6 consecutive weeks. The patient is instructed to remove the splint only to wash the finger, maintaining DIP extension all the time. Breaking these rules is the only cause of failure of conservative treatment!

The results are good or excellent in 80% of cases. In handball players, percutaneous trans-DIP pinning is not indicated because of the potential risk of infection. Moreover, this technique does not exempt from wearing a splint.

Surgical treatment

Surgical treatment of bony mallet is controversial because of the potential of this joint for remodelling. It is generally accepted that a displaced fragment greater than 1/3 of the articular surface is an indication for surgery. Operative repair also can be considered for failure of conservative therapy, whereby there is persistent subluxation despite splinting. Many techniques are described: pinning, screws, cerclage, tension band wiring or

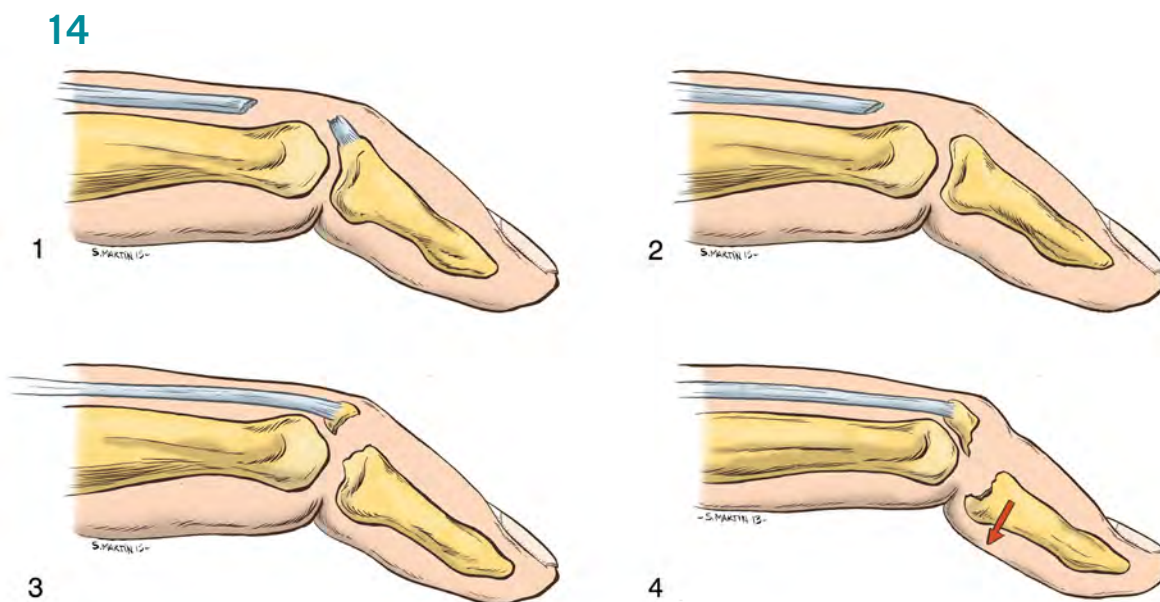


Figure 13: Lateral view of the middle finger demonstrates avulsion fracture from the dorsal base of the distal phalanx.

Figure 14: Classification of mallet finger. 1=rupture, 2=avulsion, 3=avulsion fracture, 4=fracture dislocation.



Figure 15: Dorsal thermoplastic splint.

mini anchors. This is a difficult operation that allows no margin of error due to the size and fragility of the fragment.

After conservative or surgical treatment, gentle active flexion is recommended after 6 weeks (in presence of a fracture) or 8 weeks (if no fracture). If a flexion deformity persists, splinting should be continued.

Return to sports is allowed 3 months after a mallet finger.

Complications

The use of a dorsal splint can cause maceration and/or atrophy or even skin necrosis. There is often a burning sensation or hypersensitivity that resolves with time. In case of persistent extension deficit (secondary mallet finger) or recurrence of the deformity, it is permissible to impose a new period of immobilisation of 6 weeks. The absence or failure of treatment can lead to swan neck deformity (PIP hyperextension, DIP flexion). Moreover, the finger can stiffen gradually with onset of irreducible deformity. Secondary osteoarthritis is the result of untreated or inadequately reduced bone fragment.

Key points

- Mallet finger lesions are frequent in ball sports.
- There is a characteristic deformity.
- Lateral view of the DIP is essential.
- Conservative treatment is the gold standard.

CONCLUSION

Hand injuries are very common especially in young players who are still developing their technique of receiving the ball. Most often, treatment is conservative however in some cases, surgical treatment is needed such as in rupture of medial collateral ligament of the thumb. Very frequently handball players return to play too early with protection which means long-term results are not as good as they should be which is why we must protect young players with adequate, early treatment.

References

1. Chick G. Overview of the game and the relationship between the ball and the hand. In Chick G ed. *Acute and chronic injuries in ball sports ball sport*. Paris: Springer 2013. p. 1-23.
2. Rettig AC. Epidemiology of hand and wrist injuries in sports. *Clin Sports Med* 1998; 17:401-406.
3. Peterson JJ, Bancroft LW. Injuries of the fingers and thumb in the athlete. *Clin Sports Med* 2006; 25:527-542.
4. Amadio PC. Epidemiology of hand and wrist injuries in sports. *Hand Clin* 1990; 6:379-380.
5. Knobloch K, Rossner D, Jagodzinski M, Zeichen J, Gössling T, Martin-Schmitt S et

al. Prevention of school sport injuries-an analysis of ball sports with 2234 injuries. *Sportverletz Sportschaden* 2005; 19:82-88.

6. Moutet F, Guinard D, Lebrun C, Bello-Champel P, Massart P. Metacarpophalangeal thumb sprains based on experience with more than 1000 cases. *Ann Chir Main* 1989; 8:99-109.
7. Bianchi S, Hoffman D, Almusa E. When to order specific radiological investigations? In Chick G ed. *Acute and chronic finger injuries in ball sports*. Paris: Springer 2013. p. 108-124.
8. Freiberg A, Pollard BA, Macdonald MR, Duncan MJ. Management of proximal interphalangeal joint injuries. *Hand Clin* 2006; 22:235-242.
9. Stener B. Displacement of the ruptured ulnar collateral ligament of the metacarpophalangeal joint. *J Bone Joint Surg Am* 1962; 44:869-879.
10. Guinard D, de Soras X, Gérard Ph, Thomas D. Fractures et lésions articulaires des doigts dans les sports de ballon. In Allieu Y ed. *La main du sportif*. Paris: Expansion Scientifique Française 1995.
11. Patel S, Potty A, Taylor EJ, Sorene ED. Collateral ligament injuries of the metacarpophalangeal joint of the thumb: a treatment algorithm. *Strategies Trauma Limb Reconstr* 2010; 5:1-10.
12. Lee AT, Carlson MG. Thumb metacarpophalangeal joint collateral ligament injury management. *Hand Clin* 2012; 28:361-370.
13. Aronowitz ER, Leddy JP. Closed tendon injuries of the hand and wrist in athletes. *Clin Sports Med* 1998; 17:449-467.
14. Wilson RL, Fleming F. Treatment of acute extensor tendon injuries. In Hunter JM, Schneider LH, Mackin EJ eds. *Tendon and nerve surgery in the hand, a third decade*. St Louis: CVMosby 1997. p. 567-576.

Gregoire Chick M.D.

Consultant Hand Surgeon

Geneva, Switzerland

and

Visiting Surgeon

Aspetar – Orthopaedic and Sports Medicine Hospital

Doha, Qatar

Contact: chick@la-main.ch

www.la-main.ch