

CHRONIC GROIN PAIN AMONG ATHLETES

DIAGNOSTIC APPROACH

– Written by Hashel Al Tunaiji and Karim Khan, Canada

Chronic groin pain is a common presentation in sports that involve kicking and twisting movements at high speed (e.g. soccer/football). The purpose of this paper is to introduce the reader to different diagnostic approaches to evaluate athletes with chronic groin pain.

CLINICAL ENTITY

Holmich¹ and Bradshaw² reported two approaches to diagnostic classification of groin injuries. They found that the most common pathologies were chronic adductor dysfunction, osteitis pubis (also known as pelvic ring overload, pubic bone stress injury or athletic pubalgia), hip pathology, iliopsoas pathology and abdominal wall deficiency (Figure 1). These pathologies can exist alone or in combination. The challenge remains to determine which of these pathologies causes pain.

USING THE 'GROIN TRIANGLE' AS AN AID TO DIAGNOSIS

The groin triangle³ is a suggested pathoanatomical approach that allows clinicians to discriminate systematically between different fascial, musculoskeletal and neurovascular pathologies in the groin region. This approach is based on a diagnostic triangle that is formed by connecting three landmarks: the anterior superior iliac spine, pubic tubercle

and mid-thigh point (3G) (Figure 2). This divides the groin region into the superior border, the medial border, the lateral border and within the triangle. The authors emphasise provocative and alleviating manoeuvres with minimal investigation. They also propose the pubic clock concept as a palpation guide (Figure 3). The examiner should palpate relevant attachments to pubic tubercles. The causes of chronic groin pain in different borders are presented in Table 1. This approach

addresses anatomy complexity and the clinical diagnostic challenges of the groin region. It may help less-experienced clinicians with the diagnostic process.

PATIENT-REPORTED OUTCOMES

Clinical diagnosis and subsequent intervention decisions should be shared between the clinician and the athlete. The athlete should be at the centre of this process. Patient-reported outcomes provide the clinician with the patient's

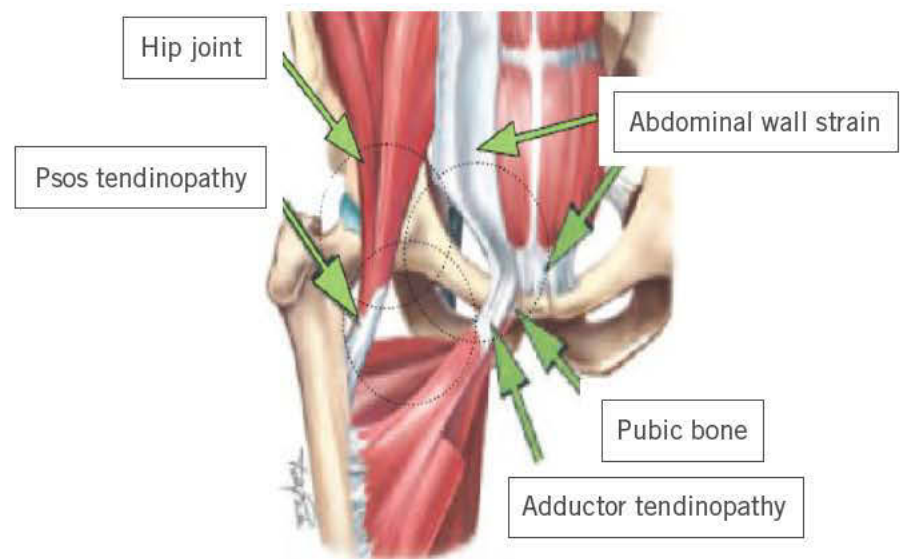


Figure 1: Overlapping clinical entities of chronic groin pain in athletes¹⁰ (sourced from Brukner & Khan's Clinical Sports Medicine, reproduced with permission from McGraw Hill Medical Australia Pty Ltd, copyright notice 2011).

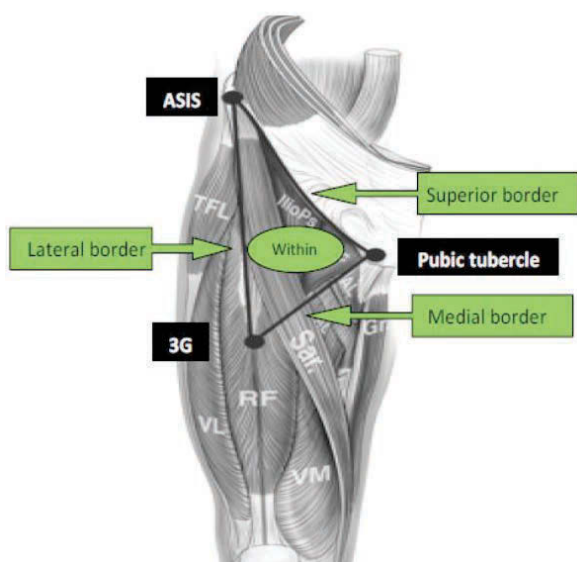


Figure 2: Anatomical landmarks of the groin triangle: anterior superior iliac spine, 3G and pubic tubercle³ (reproduced with permission from BMJ Publishing Group Ltd, copyright notice 2011).

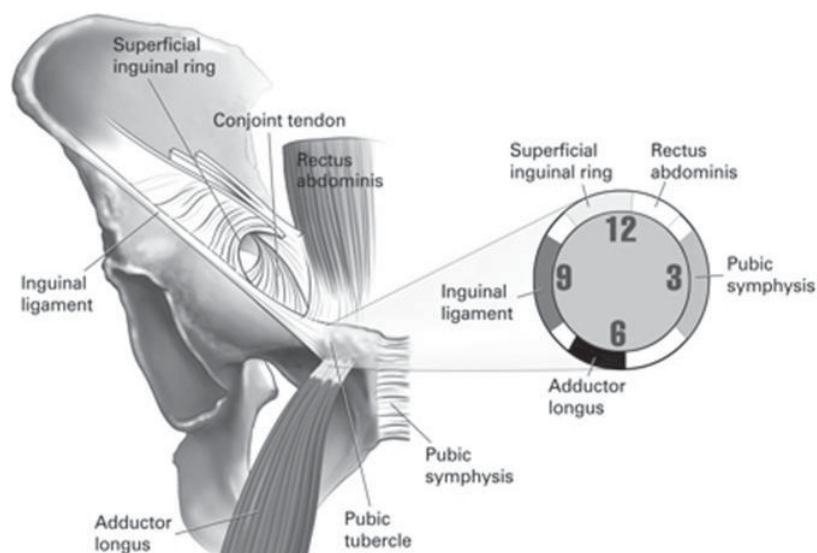
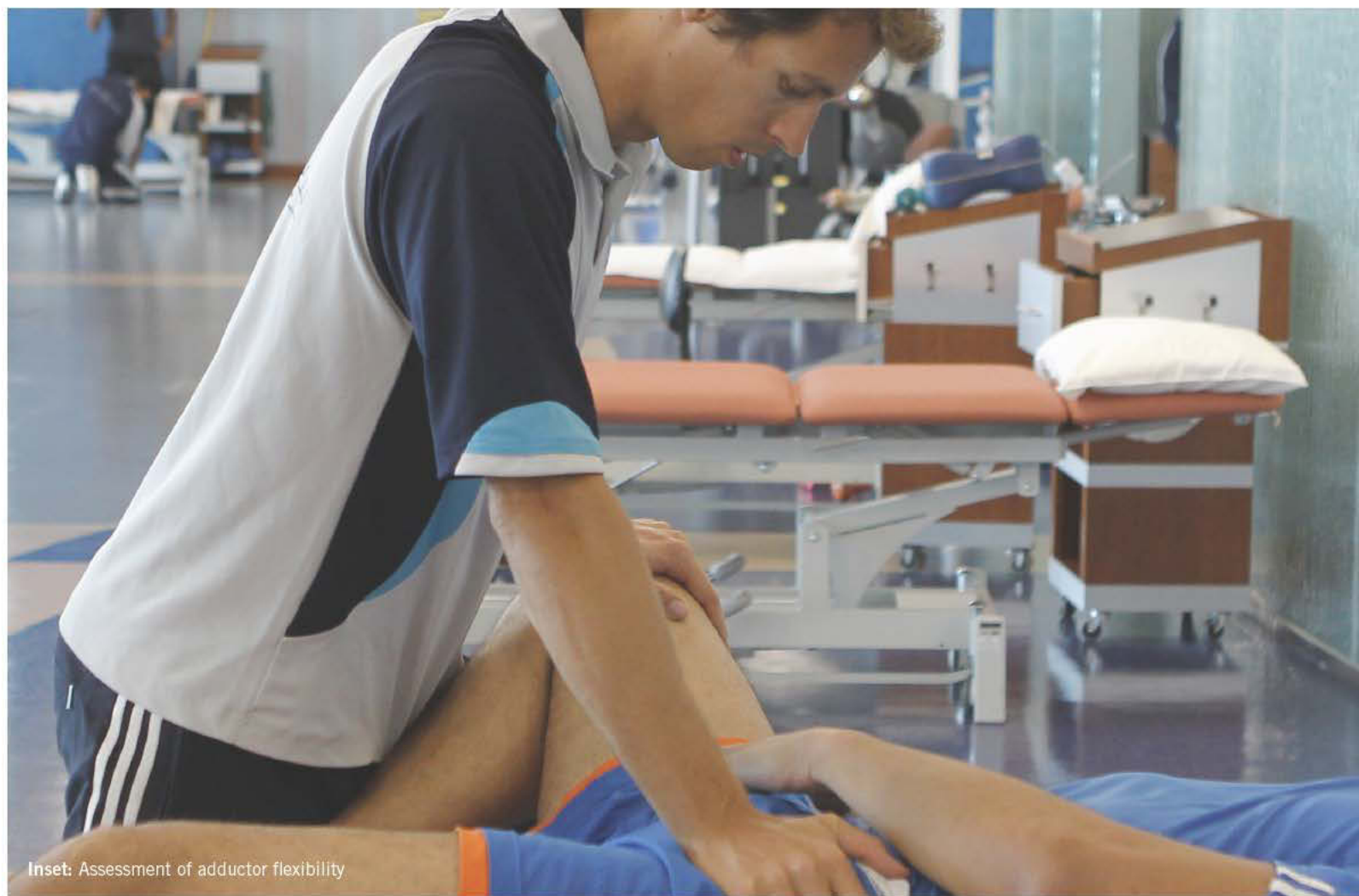

Figure 3: The pubic clock concept³ (from Falvey EC et al. Reproduced with permission from BMJ Publishing Group Ltd, copyright notice 2011).

BORDER	COMMON	LESS COMMON	NOT TO BE MISSED
Medial	<i>Adductors-related pubic bone stress injury</i>	<i>Inferior pubic ramus stress fracture Nerve entrapment Obturator nerve Ilioinguinal nerve Genitofemoral nerve (genital branch) External iliac artery endofibrosis</i>	<i>Intra-abdominal pathology Radiculopathy Avascular necrosis of femoral head Systemic diseases Metastases Tumours</i>
Lateral	<i>Hip joint Femoroacetabular impingement Labral injury Osteoarthritis</i>	<i>Iliotibial band friction syndrome Femoral neck stress fracture Nerve entrapment Lateral femoral cutaneous nerve</i>	
Superior	<i>Abdominal wall-related Rectus abdominis Conjoint tendon External oblique Hernia</i>	<i>Nerve entrapment Ilioinguinal nerve Iliohypogastric nerve Genitofemoral nerve (genital branch) Lateral femoral cutaneous nerve</i>	
Within	<i>Iliopsoas-related</i>	<i>Rectus femoris Femoral hernia Nerve entrapment Genitofemoral nerve (femoral branch) Medial femoral cutaneous nerve</i>	

Table 1: Common clinical entities of chronic groin pain among athletes in relation to different borders of the groin triangle.



Inset: Assessment of adductor flexibility

perspectives of their health-related quality of life and serve as a valuable assessment tool for understanding the symptoms and functional limitations of the injured athlete. Patient-reported outcomes are classified as either generic (applying for any condition) or disease specific⁴. The Copenhagen Hip and Groin Outcome Score⁵ is a musculoskeletal disease-specific outcome measure that has adequate psychometric properties (reliability, validity and responsiveness) in assessing symptoms, limitation, participation and quality of life among physically active young to middle-aged patients with longstanding hip and/or groin pain.

HOW TO INVESTIGATE AN ATHLETE WITH GROIN PAIN

Imaging

The pathology associated with chronic groin pain can be obvious or subtle. Therefore, the imaging approach is largely dictated by clinical findings and a high index of suspicion. Pelvic X-ray may reveal



The pathology associated with chronic groin pain can be obvious or subtle. Therefore, the imaging approach is largely dictated by clinical findings



pubic and hip-related pathologies, such as pubic instability (using flamingo stress view), hip osteoarthritis, femoroacetabular impingement or stress fracture of the femoral neck. However, magnetic resonance imaging is the diagnostic tool of choice⁶. The wide magnetic resonance imaging coronal view provides a screening tool of the hip and may initiate further imaging. It is very useful in showing abnormalities of the surrounding muscles and tendons, effusion of the pubis symphysis, extrusion of intra-articular disk,

femoral neck stress fracture, bone marrow oedema and labral injuries^{7,8}. Bone scan can be useful when stress fracture is suspected in the pubic bone or femoral neck areas; however, this investigation is associated with a large radiation dose. Ultrasound has a limited use in the detection of hernias and inguinal wall deficiency⁹.

Peripheral nerve palsies or entrapment

If suspected, elimination of symptoms by local anaesthetic infiltration and nerve conduction studies can be considered.



References

1. Hölmich P. Long-standing groin pain in sportspeople falls into three primary patterns, a "clinical entity" approach: a prospective study of 207 patients. *Br J Sports Med* 2007; 41:247-252.
2. Bradshaw CJ, Bundy M, Falvey E. The diagnosis of longstanding groin pain: a prospective clinical cohort study. *Br J Sports Med* 2008; 42:851-854.
3. Falvey EC, Franklyn-Miller A, McCrory PR. The groin triangle: a patho-anatomical approach to the diagnosis of chronic groin pain in athletes. *Br J Sports Med* 2009; 43:213-220.
4. Suk M, Hanson B, Norvell D, Helfet D (eds). *AO Handbook: musculoskeletal outcomes measures and instruments*. Thieme, New York 2005.
5. Thorborg K, Hölmich P, Christensen R, Petersen J, Roos EM. The Copenhagen Hip and Groin Outcome Score (HAGOS): development and validation according to the COSMIN checklist. *Br J Sports Medicine* 2011; 45:478-491.
6. Jansen JA, Mens JM, Backx FJ, Stam HJ. Diagnostics in athletes with long-standing groin pain. *Scand J Med Sci Sports* 2008; 18:679-690.
7. Meyers WC, Yoo E, Devon ON, Jain N, Horner M, Lauencin C et al. Understanding "sports hernia" (athletic pubalgia): the anatomic and pathophysiologic basis for abdominal and groin pain in athletes. *Operative Techniques in Sports Medicine* 2007; 15:165-177.
8. Omar IM, Zoga AC, Kavanagh EC, Koulouris G, Bergin D, Gopez AG et al. Athletic pubalgia and "sports hernia": optimal MR imaging technique and findings. *Radiographics* 2008; 28:1415-1438.
9. Koulouris G. Imaging review of groin pain in elite athletes: an anatomic approach to imaging findings. *Am J Roentgenol* 2008; 191:962-972.
10. Brukner P, Bahr R, Blair S, et al. *Brukner & Khan's Clinical Sports Medicine*. 4th ed. Sydney, McGraw Hill 2012.

CLINICAL PEARLS

- Chronic groin pain may need a multidisciplinary team approach.
- Hip-joint pain is deep and radiates to the medial thigh but generally does not travel below the knee (consider referred pain from the lumbar spine if pain extends below the knee).
- Internal rotation is the most commonly compromised motion for hip osteoarthritis.
- Functionally predominant neurological symptoms need an immediate aggressive diagnostic approach.
- In the female athlete, gynaecological pathologies can refer pain to the groin region.
- Unmask the culprit (cause) of disease process to heal the victim and prevent recurrence.
- Metastatic tumours frequently invade the hip region.

SUMMARY

Groin pain remains a major clinical challenge. A team approach is often needed to address chronic groin pain successfully.

Hashel Al Tunaiji, M.D., M.Sc.

Center for Hip Health and Mobility and
Department of Family Practice, University
of British Columbia, Canada and Sports
Medicine Center, Zayed Military Hospital,
Abu Dhabi, United Arab Emirates.

Karim M. Khan M.D., Ph.D.

Center for Hip Health and Mobility and
Department of Family Practice, University
of British Columbia, Canada.