

TREATMENT OPTIONS FOR ACROMIOCLAVICULAR JOINT SEPARATION

– Written by Li Fenglong and Jiang Chunyan, China

Acromioclavicular (AC) joint separations are common injuries that affect the shoulder girdle. Athletes from contact sports are more likely to suffer from AC separations compared with the general population. The options for treatment depend on factors including the severity of separation, the patient's age, as well as the pre-injury activity level. Treatment decisions should only be made once anatomy, biomechanics, injury pattern and classification of AC separations are fully understood.

ANATOMY AND BIOMECHANICS

The AC joint is a diarthrodial joint between the distal clavicle and the medial facet of the acromion. The motion of the AC joint is minimal, but it plays a part in normal shoulder function. During the elevation of the arm, the clavicle rotates about 40° and 5° to 8° of rotation occurs at the AC joint. Any attempts to use coracoclavicular (CC)

screws or rigid fixations along the AC joint may cause hardware failure due to the elimination of the joint motion.

The stabilising system of the AC joint includes static stabilisers (AC ligaments and CC ligaments) as well as dynamic stabilisers (deltoid and trapezius muscles). The horizontal stability of the AC joint is provided by the joint capsule and capsular ligaments (AC ligaments), while the vertical stability is provided by the CC ligaments which are composed of trapezoid ligament and conoid ligament. Fukuda et al¹ found that the AC ligaments accounted for the primary posterior and superior stability of the joint with small separation. During larger displacement, the conoid ligament tended to account for the primary superior stability, while the AC ligaments still maintained the primary posterior stability. The optimal surgical treatments for the AC separations require the reconstructions of

both AC and CC ligaments in order to prevent any horizontal or vertical translation of the distal clavicle.

MECHANISM OF INJURY

AC joint separations are typically caused by direct trauma to the shoulder as a result of a fall or during contact sports when the patient's arm is adducted. The acromion is usually impacted by the force in a superolateral to inferomedial direction as the clavicle tends to hold its anatomic position, thus leading to a spectrum of disruptions of the AC and CC ligaments. The stabilising structures are sequentially involved according to the intensity of the impacting force, starting with the AC ligaments, then the CC ligaments and lastly, the deltotrapezial fascia. Besides the mechanism of the direct impact, an indirect situation may also be introduced by a fall on the outstretched arm which could

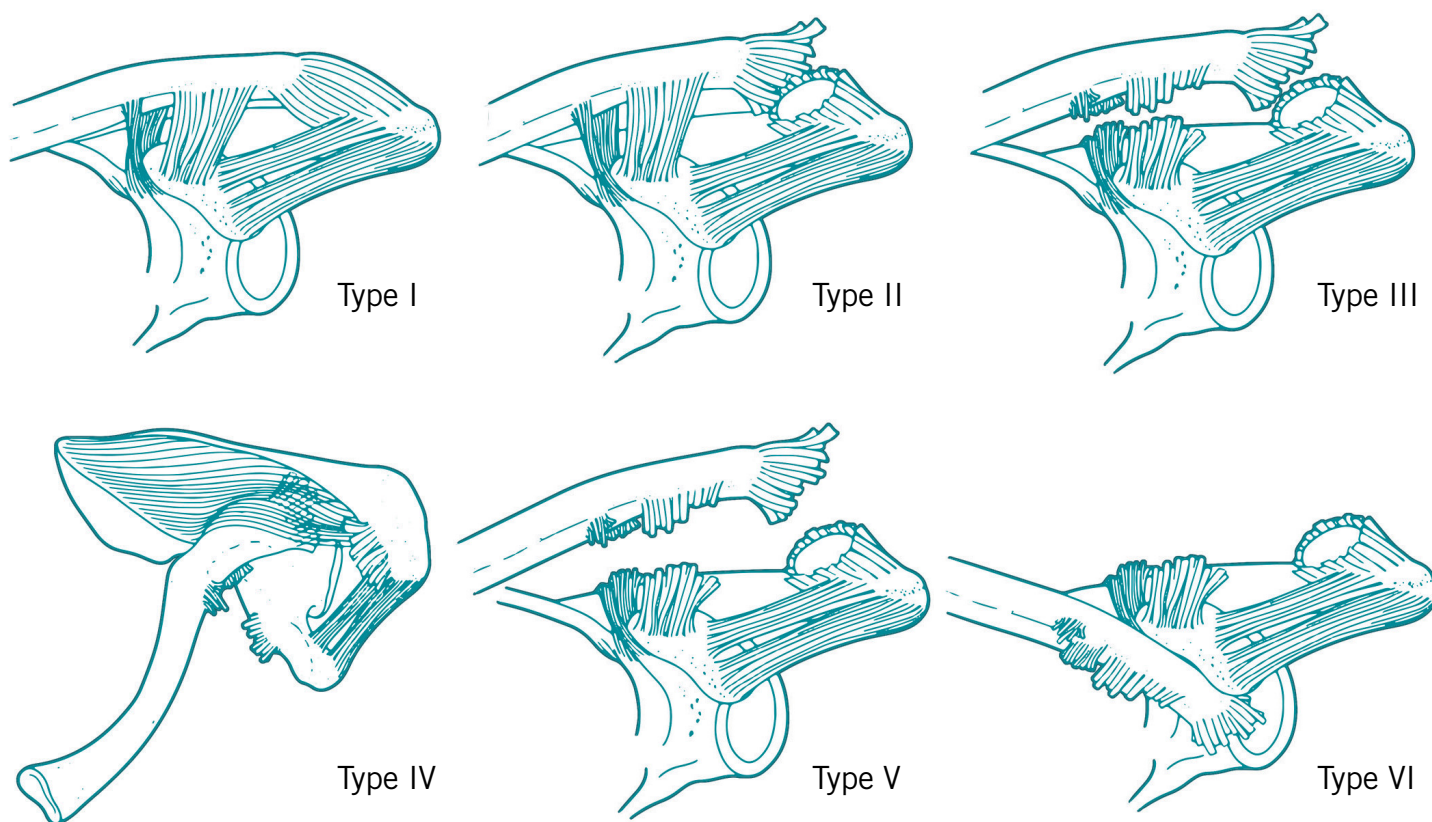


Figure 1: Rockwood classification system for AC separations.

transmit the force to the inferior aspect of the acromion through the humeral head, resulting in the AC injuries.

CLASSIFICATION OF AC SEPARATIONS

One of the most commonly used classification systems for AC separations was developed by Rockwood et al² in 1984. According to the classification (Figure 1), six types of AC injuries are classified on the basis of the severity and direction of displacement of the distal clavicle, the integrity of the AC and CC ligaments and the involvement of the deltotrapezial fascia.

Type-I

A type-I separation is usually caused by a mild force, resulting in a sprain of fibres of the AC ligaments, while the integrity of the AC and CC ligaments is still complete. The AC joint is stable without any palpable deformity. Clinicians could make the diagnosis by the injury pattern as well as minimal to moderate tenderness of the AC joint.

Type-II

A type-II separation is caused by a moderate force which is severe enough to tear the AC ligaments, meanwhile causing a sprain of the CC ligament. The distal clavicle becomes unstable despite the intact CC ligaments. The AC joint may be further widened with medial rotation of the scapula. Moderate to severe pain at the AC joint with minor deformity can be detected upon physical examination. Vertical translation of the distal clavicle could lead to an increase of the CC distance of less than 25% compared with the contralateral side. There could be horizontal instability of the AC joint due to the rupture of the AC ligaments. Clinicians may detect a minor motion of the joint while manipulating the clavicle in the anteroposterior direction.

Type-III

In a type-III separation, both the AC and CC ligaments are completely torn. The CC distance can increase by 25 to 100% compared with that of the contralateral

side as a result of the vertical translation of the distal clavicle. An obvious deformity of the prominence of the distal clavicle can be detected upon physical examination. Rupture of the CC ligaments leads to inferior translation of the upper extremity under its own weight. The distal clavicle becomes unstable both horizontally and vertically; however the integrity of the deltotrapezial fascia is not compromised.

Type-IV

A type-IV AC separation, which is less common, is similar to a type-III injury but the distal part of the clavicle is dislocated posteriorly into the fascia of trapezius. Sometimes the distal clavicle is trapped within the muscular tissue and cannot be easily removed. On physical examination, clinicians can detect a posteriorly inclined clavicle with its distal end even tenting the skin of the posterior aspect of the affected shoulder. It is also necessary to examine the sternoclavicular (SC) joint as there is a possibility of SC dislocation combined with type-IV AC separation.

Type-V

A type-V AC separation consists of similar disorders of the AC and CC ligaments as detected with a type-III injury, except the additional rupture of the deltoid fascia. The distance between the clavicle and the coracoid increases as much as 100 to 300% compared with the uninjured side. A very prominent distal end of the clavicle can be easily detected upon examination and sometimes it may even compromise the skin that covers the AC joint.

Type-VI

A type-VI AC separation is very rare and is typically caused by the abduction force through the arm during high-energy trauma. The distal clavicle is dislocated to the subcoracoid space, posterior to the tip of the coracoid process and the conjoined tendons. Clinicians can find a flattened shoulder with a prominent acromion and can easily touch the superior aspect of the coracoid process. Concomitant injuries such as the fractures of clavicle and ribs as well as brachial plexus injuries should be carefully detected.

CLINICAL RELEVANCE

AC joint injuries should be considered in any patient who has undergone a traumatic event related to the shoulder. In order to make an appropriate treatment decision, clinicians should record the patient's age, injury pattern, as well as pre-injury type of sport and level in detail. On physical examination, clinicians may inspect the contour of the affected shoulder by letting the patient take a seated position so as to detect any subtle deformity of the AC joint. Both shoulders should be examined to determine the extent of the deformity. The shoulder should be carefully inspected both superiorly and anteriorly in order to identify any horizontal and/or vertical displacements of the AC joint. The AC joint, the entire clavicle and the SC joint should be carefully palpated in order to locate the injured site as well as to determine the inclination of the clavicle from medial to lateral. The tenderness of the AC joint may be accentuated by cross-body adduction of the involved arm, which increases the tension of the AC joint. Tenting of the skin by the distal clavicle may be detected in a type-III or type-V AC separation. The SC joint could be involved concomitantly in a type-

IV AC separation. Transient paresthesia of the affected extremity may be present in a type-VI AC separation. If subluxation or dislocation of the AC joint is detected, clinicians could try gently to reduce the distal clavicle to restore the alignment of the AC joint and determine the type of the AC separation.

Radiographic evaluation

A set of standard shoulder views including anteroposterior, lateral and axillary views could be obtained upon suspicion of the AC separations. The traditional anteroposterior view taken with a horizontal-beam projection may result in superimposition of the AC joint over the scapular spine, leading to misdiagnosis. Zanca³ improved this situation by adjusting the beam to a 10° to 15° cephalic tilt, which may help to maximise the visualisation of the AC joint. In case of a minor separation of the joint, Zanca views of both sides may be obtained to make a comparison. The enlargement of the vertical CC distance can be determined compared when with the

uninjured shoulder on the anteroposterior radiograph, with an increase of less than 25% for type-II AC separation, 25 to 100% for type-III and 100 to 300% for type-V. An axillary view is necessary to evaluate any posterior displacement of the distal clavicle, as this may be present in the type-IV AC separation.

TREATMENT OF AC SEPARATIONS

Type-I

Non-operative treatment can be applied for the type-I AC separation. Sling immobilisation for 1 week is necessary. For pain relief, ice therapy can be applied for the first 48 hours after injury and anti-inflammatory medications could also be recommended. Physical therapy including passive and active range-of-motion exercises may begin as soon as the symptoms resolve. Strengthening exercises can be initiated after a full recovery of range of motion of the affected shoulder. Patients' return to full activities is allowed when a painless active range of motion is fully restored. For a type-I separation, it usually takes 2 weeks for most athletes to return to full activities.





AC joint injuries should be considered in any patient who has undergone a traumatic event related to the shoulder



Type-II

Treatment of type-II AC separations is mostly the same as that of a type-I separation. However, due to the more extensive trauma of the soft tissue, a sling immobilisation of 2 to 3 weeks may be necessary. Clinicians should inform patients that there is a chance for the type-II AC separation to develop into post-traumatic degenerative arthritis with persistent symptoms and that a mild deformity may remain despite the healing of the injury. If the symptoms are not responsive to conservative treatments, an open or arthroscopic distal clavicle resection may be a treatment option.

Type-III

The treatment of type-III AC separations has been controversial. Clinicians should take full consideration of the patient's age, occupation, hand dominance, functional demand of work or sports, as well as the risk of reinjury before making any treatment decision. Although there are a limited number of studies with high-level evidence to compare the results of non-surgical treatment with that of operative treatment for type-III AC separations, the current consensus is that there is no functional difference between the conservative treatment group and the surgical treatment group. Patients from the surgical treatment group have a higher complication rate as well as a longer duration of recovery before return to pre-injury levels of activity. In general, type-III AC separations should be managed with an initial trial of conservative treatment for 3 to 4 months, which is essentially the same as that for type-I and type-II separations, except a longer

time frame. Operative treatment may be indicated for patients who have significant deformity of the AC joint, chronic pain or instability unresponsive to conservative treatments, as well as for patients who claim a higher functional requirement of the affected shoulder in order to return to pre-injury positions or sports.

Types-IV, V and VI

Early surgical intervention is recommended for the treatment of type-IV, type-V and type-VI AC separations in patients who are medically stable. Numerous operative procedures have been described for the treatment of both acute and chronic AC separations.

SURGICAL TREATMENT OPTIONS

A variety of surgical techniques have been reported for the treatment of type-III AC separations which are unresponsive to non-operative management, as well as for the treatment of type-IV and type-V AC separations. However, there is no evidence to support one technique as the gold standard. The most mentionable techniques in the literature include AC joint fixation with implants, coracoacromial (CA) ligament transfer and CC interval reconstruction. All these procedures have various modifications. Clinical studies have reported good outcomes from different surgical procedures, however these studies are mostly either low-level retrospective ones or prospective studies with a limited sample size. Clinical studies with a higher level of evidence are required to identify the most appropriate surgical technique for AC separations.

AC JOINT FIXATION

Early surgical techniques for AC joint fixation included the use of K-wires or pins implanted through the AC joint. However, due to the high complication rates, including implant migration and loss of reduction, surgeons tend to avoid using these techniques⁴.

For the treatment of type-III separations, the use of hook-plates has been reported with better results compared with non-surgical management⁵. However, the need to remove the implant 2 to 3 months after the first operation, as well as complications such as impingement, implant failure and acromion erosion, have compromised the favour of the use of hook-plates.

CA LIGAMENT TRANSFER

In 1972, Weaver and Dunn⁶ described a classic technique, which included the resection of the distal portion of the clavicle, as well as transferring the CA ligament from the acromial aspect to the distal clavicle for the treatment of complete AC joint separations. Although several modifications to the original Weaver-Dunn procedure had been reported with good outcomes, the rate of loss of reduction was noted to be up to 20%⁷. In some biomechanical studies, the CA ligament was found to have inferior performance compared with the original AC ligaments. Due to the biomechanical limitations, some authors recommended the use of CA ligament transfer combined with CC reconstruction by screws, grafts or sutures.

CC INTERVAL RECONSTRUCTION

CC interval reconstruction consists of CC ligament reconstruction, as well as CC fixation with screws, high-performance sutures, suture anchors or endobuttons. Although the use of CC fixation techniques with different implants has been reported with acceptable results, simple rigid fixation may concentrate the loads to the fixation portions on the distal clavicle and the coracoid process, leading to implant failure, osteolysis or even fracture of the clavicle or coracoid process. On the other hand, there has been an increasing trend to use the technique of CC ligament reconstruction and the short-term outcomes are promising. CC ligament reconstruction combined with CC fixation with synthetic materials has been more and more popular in the treatment

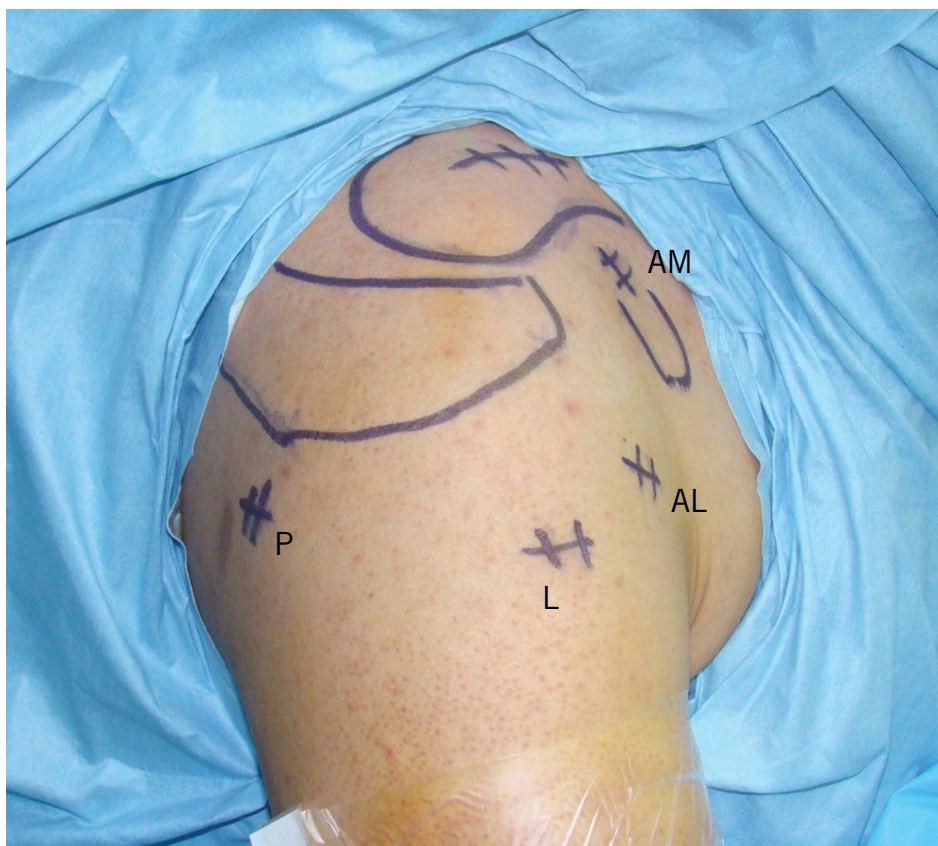

Figure 2: Portals applied in the arthroscopic surgery for AC separations. P=primary posterior portal, L=lateral subacromial portal, AL=anterior lateral portal, AM=anterior medial portal.

of AC separations. The additional use of CC fixation would protect the integrity of the reconstructed structures, as well as maintain the stability of the AC joint and CC interval during the early healing stage of the reconstructed complex, thus improving the biomechanical characteristics and surgical outcomes.

ARTHROSCOPIC TECHNIQUES

With the development of arthroscopic techniques, surgeons tend to treat AC separations with the use of arthroscopy. The advantage of the arthroscopic reconstruction is that surgeons may perform a full inspection to evaluate and address the concomitant injuries such as rotator cuff tears and labral lesions, while the limited soft-tissue invasion may facilitate the rehabilitation process and the early return to pre-injury activities. The limitations of arthroscopic reconstruction are the technical difficulties and learning curves that surgeons are confronted with.

Currently, we prefer arthroscopic CC ligament reconstruction with the CC sling technique. The indications of this technique are fresh AC joint injuries including type-

IV and type-V AC separations, as well as type-III separations in patients with higher functional requirements. During surgery, the primary posterior portal, lateral subacromial portal, anterior lateral portal and anterior medial portal are established (Figure 2). The prepared hamstring allograft along with the high-performance sutures is passed under the base of coracoid process, behind the insertion of the CA ligament. The limbs of the graft and sutures are guided through the two drill holes on the clavicle right above the coracoid process. After the arthroscopic confirmation of the reduction of the AC joint, the sutures are tied and the two limbs of the graft are secured to each other with absorbable sutures.

SUMMARY

AC joint separations are common injuries around the shoulder girdle. Treatment decisions should be made upon full consideration of the patient's age, hand dominance, functional demand of work or sports, as well as the types of separations. Type-I and type-II separations should be managed conservatively. Surgical treatment is recommended for patients with type-

III separations which are unresponsive to non-operative managements and lastly for patients with type-IV, type-V and type-VI separations. Numerous surgical techniques have been described to address AC separations, of which reconstructive techniques have been increasingly employed with promising results.

References

1. Fukuda K, Craig E, An KN, Cofield RH, Chao EY. Biomechanical study of the ligamentous system of the acromioclavicular joint. *J Bone Joint Surg Am.* 1986; 68:434-440.
2. Rockwood CA Jr. Injuries to the acromioclavicular joint. In: Rockwood CA Jr, Green DP, eds. *Fractures in adults*, vol 1, 2nd ed. Philadelphia: JB Lippincott 1984. p.860-910.
3. Zanca P. Shoulder pain: involvement of the acromioclavicular joint. (*Analysis of 1000 cases*). *Am J Roentgenol Radium Ther Nucl Med* 1971; 112:493-506.
4. Lyons FA, Rockwood CA Jr. Migration of pins used in operations on the shoulder. *J Bone Joint Surg Am* 1990; 72:1262-1267.
5. Gstettner C, Tauber M, Hitzl W, Resch H. Rockwood type III acromioclavicular dislocation: surgical versus conservative treatment. *J Shoulder Elbow Surg* 2008; 17:220-225.
6. Weaver JK, Dunn HK. Treatment of acromioclavicular injuries, especially complete acromioclavicular separation. *J Bone Joint Surg Am* 1972; 54:1187-1194.
7. Weinstein DM, McCann PD, McIlveen SJ, Flatow EL, Bigliani LU. Surgical treatment of complete acromioclavicular dislocations. *Am J Sports Med* 1995; 23:324-331.

Li Fenglong M.D.

Jiang Chunyan M.D.

Shoulder Service

Beijing Ji Shui Tan Hospital,

Beijing, People's Republic of China

Contact:long_bmu@163.com