

DYNAMIC KNEE LAXITY MEASUREMENT

DOES IT CHANGE ACL SURGICAL INDICATIONS?

– *Written by João Espregueira-Mendes, Renato Andrade, Ricardo Bastos and Rogério Pereira, Portugal*

The anterior cruciate ligament (ACL) is one of the most commonly injured knee ligaments in sports worldwide, often requiring reconstructive surgery. Several factors have been identified that predispose individuals to a higher risk of injury, including anatomical, environmental and biomechanical risk factors. Identification of the predisposing risk factors, particularly those that are modifiable, allows the implementation of safe and effective prevention programmes, which can even be fun and lead to significant health, sporting, social and economic benefits.

ACL injuries are often accompanied by meniscal damage or articular cartilage defects, which if not managed properly may result in more severe impairment of

knee structural and functional homeostasis. This can imply decreased motor skills, sporting performance and a significant decrease in overall quality of life due to its implications for different layers of activity, i.e. a cascade of negative events that hinder an athlete's sporting, individual, family and social endeavours and accomplishments. Specifically, the injury itself clearly results in increased risk of new injuries (especially young players and women) and decreases the likelihood of being able to continue a long-term career in sport at the top level¹. Moreover, if an ACL re-rupture occurs, the chance of returning to play at the same level is even more drastically lowered. Thus, chronobiological, functional and ability level of participation criteria, should be

considered for an evidence-based decision on return to play. In this sense, secondary prevention should also have a major and continued role.

Treatment algorithms for ACL injuries have been continuously evolving and the standard management of ACL injuries remains reconstructive surgery. Additionally, the anatomic and individualised ACL reconstruction concept (either single- or double-bundle approaches), taking into account the patient's native anatomy and specific demands, is considered the gold standard surgical intervention to restore normal knee kinematics, while protecting knee health in the long term. Hence, non-operative approaches may be considered for patients identified as 'copers'².



COMPREHENSIVE ASSESSMENT OF ACL INJURY

Clinical examination remains one of the most common and important diagnostic procedures for the ACL-deficient knee. The Lachman and pivot shift tests are considered the most sensitive and specific manual clinical tests, respectively³. However, clinical examination has some limitations: it is dependent on the surgeon's training, experience and technique reliability, providing inexact appreciations. Therefore, medical history, instrumented laxity testing, imaging and arthroscopy also play an important role in diagnosing an ACL rupture. In addition, it has been advocated that clinical examination, instrumented laxity testing and MRI are required in combination to obtain broader diagnostic value.

Indication for ACL reconstruction should be supported by physical examination, imaging and instrumented laxity findings

of both the disruption of the ligament and the increased ligamentous laxity. Inaccurate structural and functional diagnosis can lead to imprecise preoperative planning and therefore may increase the odds of suboptimal surgical outcomes, leading to reduced success of rehabilitation and return to play at the desired level. Improved diagnostic features are required and have been developed to better define treatment on a case by case basis.

Every healthcare professional has experienced diagnostic uncertainty based on physical examination and medical history findings. The differential diagnosis process relies on a broad knowledge of the anatomy and associated pathologies and, when applied appropriately, saves time and resources, as well as indicating the most appropriate treatment pathway.

MRI techniques play a crucial role in confirming the diagnosis and the subsequent medical management of an ACL tear.

In the case of a partial ACL rupture, this may yield significant clinical repercussions, since partial ruptures may heal or progress on their own and should be carefully followed by MRI examination⁴. Moreover, assessment of the remaining ligamentous fibres' anatomical integrity, biomechanical competence and, consequently, multiplanar arthrokinematic characterisation is of utmost importance when selecting a treatment strategy. Some partial ACL ruptures with functional remaining ligamentous fibres may not require surgical intervention and others may profit from an ACL augmentation procedure to restore and/or achieve higher knee stability, better proprioception and less stiffness than standard ACL reconstruction⁵.

MRI ASSESSMENT OF ACL INJURY

MRI assessment of the knee usually includes imaging of the ligamentous, meniscal, bony and articular cartilage structures. When an ACL injury is suspected, MRI offers high sensitivity and specificity. T2 sequences and proton density with fat saturation weighted images, using fast spin echo sequences, are most frequently used to diagnose an ACL rupture. In the acute setting, T2-weighted images and oblique coronal sections are preferable since they improve diagnostic specificity and accuracy. Nevertheless, in order to accurately diagnose an ACL rupture, it is essential to know and understand the principal signs: non-visualisation of ligament continuity, diffuse or increased signal intensity at the ACL, abrupt angulation or wavy appearance of the ligament and abnormal ACL axis⁶. Secondary signs include pivot shift bone bruises or knee osteochondral fractures, anterior subluxation of the tibia, Second fracture, tibial spine fracture, morphometry of the ACL and tibial footprint and rotational knee laxity.

KNEE LAXITY ASSESSMENT

Assessment and grading of knee envelope laxity changes from injury until return to play, have been employed




Figure 1: Porto-Knee Testing Device (PKTD®) for posteroanterior and rotational knee laxity measurement during MRI or CT evaluation.

as one indicator of the efficacy of ACL reconstructive surgery. Thus, the objective measurement of sagittal and rotatory laxity of the knee plays a key role in the diagnosis, preoperative planning and follow-up of an ACL injury. This may be accomplished statically using stress radiography, clinical examination or manual testing devices (such as, KT-1000/2000, MEDmetric Corp., San Diego, CA, USA). However, these devices present accuracy and reliability limitations⁷. As a result, diagnostic devices aimed at dynamic measurements have emerged to overcome these issues, including robotic systems, user-friendly iPad applications and stress laxity assessment during MRI^{8,9}.

FUNCTIONAL AND OBJECTIVE KNEE MULTIPLANAR LAXITY MRI ASSESSMENT

Dynamic evaluation allied to current imaging technology permits the assessment of knee joint morphology and biomechanical behaviour in different degrees of flexion, combined with postero-anterior (PA) and rotational, forces and torques, respectively. This can be accomplished by combining MRI morphological assessment with sagittal and rotational knee laxity evaluation through medical devices such as the Porto-Knee Testing Device (PKTD®, Soplast, Valongo, Portugal).

The PKTD is made of two-component polyurethane (Figure 1), allowing it to be safely used during MRI and computed tomography (CT) exams. Such devices enable testing of the knee at different degrees of flexion while assessing sagittal

laxity by transmission of a standardised PA force at the proximal calf region. In the case of an ACL tear, there will be a noticeable anterior translation of the tibia. In addition, the device is able to examine knee external and internal rotatory laxity combined with PA translation which is important as these comprise some of the most important and, at the same time, affected arthrokinematic degrees of freedom of the joint.

Tashiro et al¹⁰ suggested knee laxity measurements should be obtained by calculating the difference between two lines perpendicular to the tibial slope, one crossing the most posterior point of the tibial plateau and the other the most posterior point of the femoral condyle.

This measurement is made for both medial and lateral knee compartments and may be done in different arthrokinematic motion combinations: with or without PA translation, with or without internal and/or external rotation, or combined PA translation with internal and/or external rotation.

A previous report showed reliability in knee laxity measurements during MRI for both sagittal (correlation with KT-1000) and transversal (correlation with pivot shift test under anaesthesia) planes in ACL-deficient knees⁹. More recently, another clinical report⁸ showed increased sagittal and rotational laxity of ACL-ruptured knees (arthroscopically confirmed), when

Objective measurement of sagittal and rotatory laxity of the knee plays a key role in the diagnosis, preoperative planning and follow-up of an ACL injury

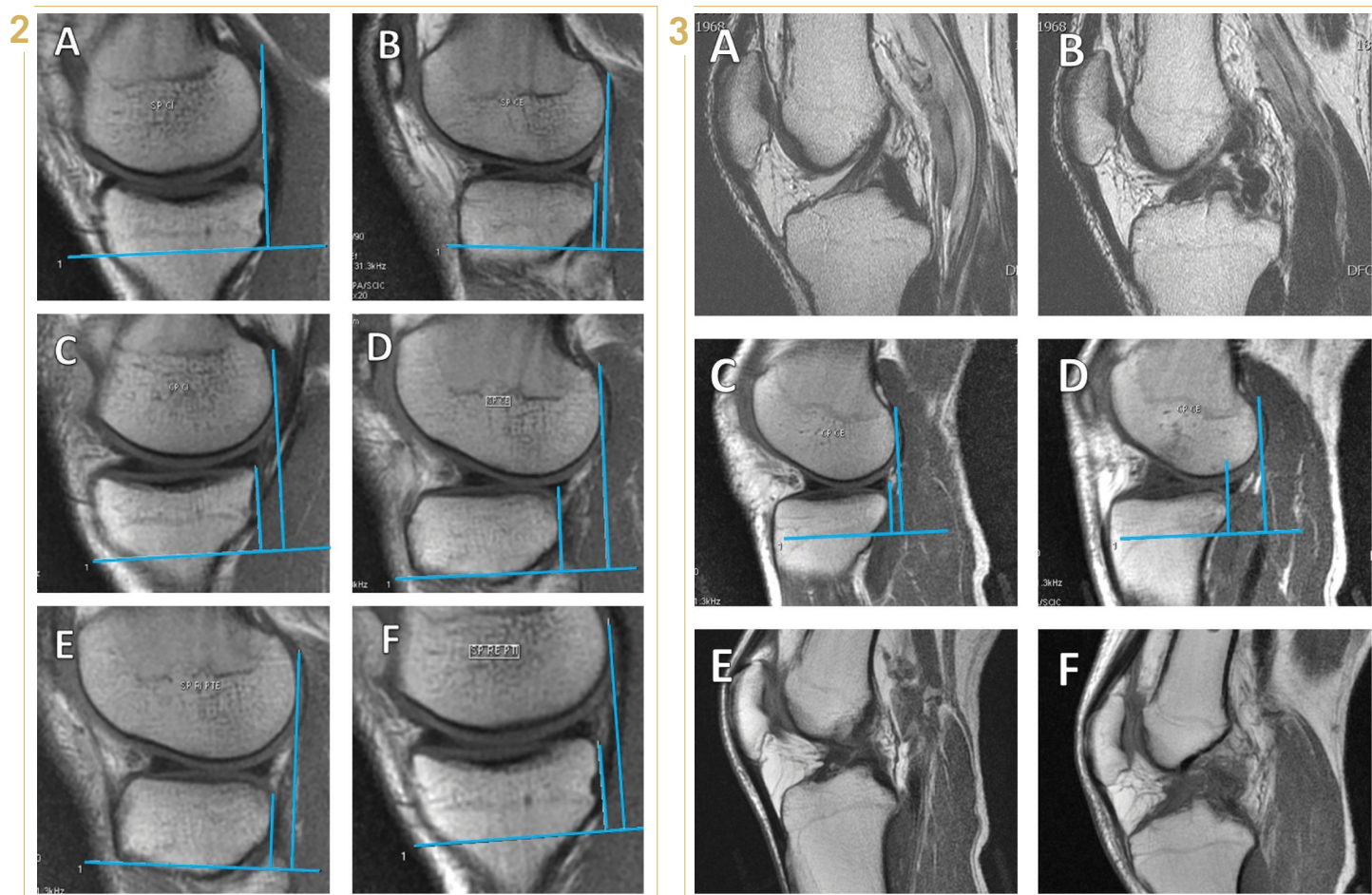


Figure 2: MRI measurements after PKTD examination for preoperative planning. (a) medial plateau, no stress (0 mm); (b) lateral plateau, no stress (3 mm); (c) medial plateau PA stress (7 mm); (d) lateral plateau PA stress (14 mm); (e) lateral plateau, maximum internal rotation (6 mm); (f) medial plateau, maximum external rotation (5 mm).

Figure 3: Chewing gum effect mechanically exposed by PKTD evaluation. (a) MRI scan of the left knee (healthy) showing ligament continuity and integrity; (b) MRI scan of the right knee (injured) where increased signal and thickening of the ligament are visible, however without evidence of ligament discontinuity and loss of integrity; (c) MRI scan with PKTD of the left knee (healthy) after PA stress, showing low-grade anterior translation (3 mm); (d) MRI scan with PKTD of the right knee (injured) after PA stress, showing high-grade anterior translation (13 mm), suggesting an ACL rupture. (e) MRI scan slice of the healthy knee with PKTD PA stress, an intact ACL can be observed; (f) MRI scan slice of the injured knee with PKTD PA stress, showing discontinuity of the ACL, evidencing a total ACL rupture. The initial suspicion of non-injured ACL or partial ACL rupture is disregarded due to evidence of chewing gum effect after PKTD evaluation.

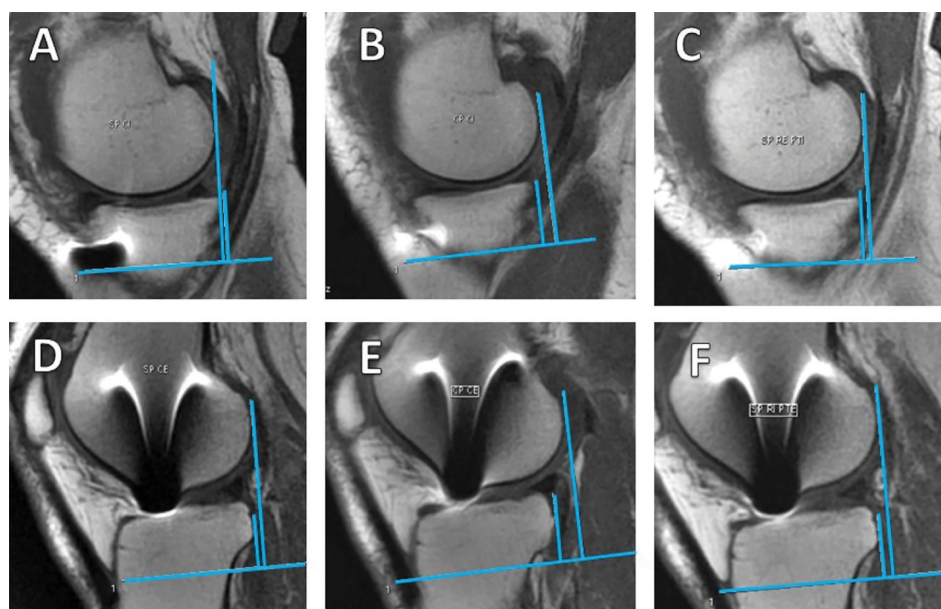


Figure 4: MRI measurements of a PKTD assessment from a patient with an ACL-reconstructed knee. (a) medial plateau, no stress (1 mm); (b) medial plateau PA stress (4 mm); (c) medial plateau, maximum external rotation (2 mm); (d) lateral plateau, no stress (2 mm); (e) lateral plateau PA stress (7 mm); (f) lateral plateau, maximum internal rotation (6 mm).

TABLE 1

| Indications | Absolute contraindications | Relative contraindications |
|--|--|--|
| Young patient (<40 years) | Partial tears | Open physes (Tanner stage ≤ 3 , males ≤ 16 years, or females ≤ 14 years) |
| Active lifestyle | Minimal instability or laxity | Radiographic evidence of degenerative joint disease (Kellgren-Lawrence grade ≥ 3) |
| Acute rupture (<6 months) | Elderly or low-demanding patients with minimal instability | Sedentary or inactive lifestyle |
| Subjective knee instability (medical history, symptoms report and functional scores) | Uncorrected knee malalignments | Unwillingness or inability to comply with the required postoperative rehabilitation protocol |
| Objective knee instability (physical examination and instrumented laxity) | Presence of unsafe comorbidities (e.g. active infection) | |

Table 1: Indications, and absolute and relative contraindications for primary ACL autograft reconstruction^{13,17}.

RECOMMENDATIONS FOR FUTURE RESEARCH

The establishment of cut-offs for knee laxity measures in different planes could have an important role for refining therapeutic indications. This implies the search for correlations between laxity measurements and strain response of the ACL remnants or graft to uniplanar and multiplanar loads, during simulated motor actions such as landing or cutting manoeuvres. The collection of biomechanical data would aid the treatment selection process and secondary prevention strategies.

compared to the healthy contralateral knee. Moreover, the anterior global translation of both tibial plateaus (PA translation of the medial and lateral tibial plateaus) and global rotation of the lateral tibial plateau (internal and external rotation of the lateral tibial plateau) were calculated and showed significant positive correlations with the Lachman and pivot shift test, respectively. Moreover, the anterior global translation and global rotation of the lateral tibial plateau were the most specific (with a cut-off point of 11.1 mm, 93.8 %) and sensitive (with a cut-off point of 15.1 mm, 92.9 %) measures, respectively. Hence, by calculating

the sagittal and rotational laxity profile, the described process of instrumented assessment proved to be a discriminant laxity testing device with high sensitivity and specificity in objectively differentiating ACL-injured and healthy knees in different planes. The high sensitivity and specificity in objectively discriminating ACL ruptures and measuring multiplanar knee laxity may be used to advocate non-operative treatment or for preoperative planning of stability restoration procedures (Figure 2).

MRI assessment of partial ACL ruptures is less reliable, even when using 3-Tesla MRI devices¹¹. Moreover, it is even more difficult

to characterise the functional behaviour of the remnant ligament and differentiate between total and partial ACL ruptures as partial ruptures may present a similar instability profile to the total ruptures¹². Identification of partial ACL ruptures would yield clinical benefits as the remnant tissue may preserve some mechanical function in knee stability¹² and some neural mechanoreceptors which may maintain knee joint proprioception. By placing stress on the ACL, we are able to evaluate both anatomical and dynamic mechanical behaviour of the remaining bundle and characterise the biomechanical status of the ligament's remnant. Additionally, the 'chewing gum effect' may also be identified by testing the mechanical behaviour of knees with a previous partial rupture (Figure 3).

The previously-described devices for knee laxity assessment can be used to mimic the dial test for posterolateral corner injuries by coupling 30° knee flexion with an external rotation force to the tibia. This evaluation must be performed bilaterally to allow comparison with the contralateral limb. Additionally, if PA translation is applied in combination with maximum tibial internal rotation, it is possible to evaluate and measure the posteromedial instability⁸.

CT evaluation is often used for the assessment of tunnel placement and surrounding bone integrity of ACL-reconstructed patients. It is also possible to add instrumented laxity measurements while performing CT and, therefore, gather extra and very useful information on laxity outcomes from ACL reconstruction. Nonetheless, exposure to CT radiation is an issue to consider – knowing that laxity assessment can be accomplished without the need for a CT scan.

non-operative approaches may be considered for patients identified as 'copers'

Dynamic MRI assessment presents novel insights into a more detailed morphological and functional evaluation, with several significant clinical advantages. In addition to the already-mentioned uses, the PKTD can help identify populations with increased risk factors for ACL rupture and, consequently, play a crucial role in tailoring prevention strategies to correct or minimise these. It can also identify individuals with a high rotational instability profile who would benefit from an ACL reconstruction technique that is able to provide greater rotatory restraint.

TREATMENT INDICATIONS

The decision on which is the best management approach should take into account the patient's age, demands of their sport or physical activities, expectations and presence of concomitant injuries. Nonetheless, ACL reconstruction is the most common approach since it is known to reduce pathological knee laxity, while decreasing the risk for subsequent associated cartilage or meniscal damage¹³. Still, ACL reconstruction is not guaranteed to prevent the development of early knee OA¹⁴. Irrazaval and colleagues¹³ defined several subjective and objective parameters to better define which patients who benefit the most from ACL reconstruction (Table 1).

For less active patients with minimal knee laxity, or when surgical management is contraindicated, non-operative treatment may be the most suitable option. Satisfactory results have been reported for non-operative treatment in ACL-deficient patients². Therefore, there is a need to better define copers and non-copers to identify those who would benefit the most from non-operative treatment. In this sense, copers are defined as athletes who are able to return to preinjury level of sports asymptotically, without surgical reconstruction of the ACL. In turn, non-copers are those who have objective (knee laxity) or subjective (functional score or episodes of giving way) knee instability or are unable to successfully return to their preinjury level of sports. Additionally, there is a third group known as adapters, which represents athletes who are able to modify their lifestyle to mitigate provocative activities that would evoke episodes of instability or giving way¹⁵. Functional testing and isokinetic evaluation seem to

assist the clinician in identifying copers and non-copers. Screening algorithms have been developed for this purpose^{2,16}.

Dynamic knee laxity measurement, as performed for instance by the MRI-PKTD, may be able to identify individuals with a high degree of knee laxity and establish additional objective criteria for surgical treatment: anterior global translation of more than 11.1 mm, and global rotation of the lateral tibial plateau of more than 15.1 mm⁸. Moreover, dynamic knee laxity measurement may also identify individuals with partial or total ACL ruptures but with laxity-related functionally competent knees, who might be potential candidates for non-operative treatment, if there is no report of recurrent subjective instability.

References available at
www.aspetar.com/journal

João Espregueira-Mendes M.D., Ph.D.
Clínica do Dragão, Espregueira-Mendes
Sports Centre - FIFA Medical Centre of
Excellence
Porto, Portugal.

Dom Henrique Research Centre
Porto, Portugal.

3B's Research Group—Biomaterials,
Biodegradables and Biomimetics
University of Minho, Headquarters of the
European Institute of Excellence on Tissue
Engineering and Regenerative Medicine
Guimarães, Portugal.

ICVS/3B's—PT Government Associate
Laboratory
Braga/Guimarães, Portugal.

Orthopaedics Department
Minho University
Braga, Portugal.

Renato Andrade B.Sc.
Clínica do Dragão, Espregueira-Mendes
Sports Centre - FIFA Medical Centre of
Excellence
Porto, Portugal.

Dom Henrique Research Centre
Porto, Portugal.

Faculty of Sports
University of Porto
Porto, Portugal.

Ricardo Bastos M.D., Ph.D.
Clínica do Dragão, Espregueira-Mendes
Sports Centre - FIFA Medical Centre of
Excellence
Porto, Portugal.

Dom Henrique Research Centre
Porto, Portugal.

Fluminense Federal University
Rio de Janeiro, Brazil.

Rogério Pereira B.H.Kin., PT., Ph.D. (c)
Clínica do Dragão, Espregueira-Mendes
Sports Centre - FIFA Medical Centre of
Excellence
Porto, Portugal.

Dom Henrique Research Centre
Porto, Portugal.

Faculty of Sports
University of Porto
Porto, Portugal.

Faculty of Health Science
University Fernando Pessoa
Porto, Portugal.