

'LE MENU À LA CARTE' IN PATELLA INSTABILITY

– Written by Cecile Batailler, France, Nader Darwich, United Arab Emirates, Simone Cerciello, Italy and Philippe Neyret, France

Symptomatic patellar instability is a significantly disabling pathology. Treatment is often recommended to improve the quality of life of patients. But when it comes to treating athletes, a lack of literature – which has largely focused on paediatric populations – has caused controversy over the best approach. Nonetheless, patellar instability – in particular patellar dislocation – is a common injury in athletes as many sports cause repetitive stress and trauma to the joint. These patients therefore need appropriate treatment and rehabilitation to avoid recurrence, improve the quality of life and return to sports. In this article, we will discuss the risk factors for athletes with closed epiphyses, treatment options, outcomes and complications – particularly focusing on return to sport.

WHICH ATHLETES ARE AT RISK OF PATELLAR INSTABILITY?

Sport activities are a significant cause of patellofemoral instability (PFI), and even of patellar dislocations. These activities result

in large repetitive forces being applied to the extensor mechanism. Mitchell et al¹ reported a PFI rate of 1.95 per 100,000 patients among high school athletes. Competition increases the risk of injury (3.72 per 100,000 high-level athletes) compared to training (1.34)¹.

Regardless of the involvement of sport, the rate of patellar dislocation is lower for girls than for boys¹. Indeed boys tend to practice sports at higher risk of patellar dislocation due to high-energy traumas (such as American football or wrestling). However, among the more gender-comparable sports (such as soccer, basketball, track and field, cross-country etc.) the rate of patellar instability is two times higher for girls than for boys.

Young athletes are also more at risk of patellar instability. A database study of American emergency departments selected to represent the demographics of the United States population estimated this incidence as 11.19 per 100,000 person years among adolescents between 15 and 19 years old². In a study of 20 young athletes³ who

suffered a traumatic patellar dislocation with secondary recurrent instabilities, the following anatomical abnormalities were reported:

- Patella alta (25%).
- Slight trochlear bump (40%).
- Femoral sulcus angle superior to 144° (30%).
- High Q angle.

These patients often have at least one anatomical abnormality, explaining the increased risk. This can cause difficulty in pursuing sport to a high level. However, anatomical abnormalities can also be found in adult athletes, these abnormalities remain moderate and isolated. For example, patella alta may be more frequent in basketball players since increased patient height may contribute to a longer tendon.

PATELLAR DISLOCATION MECHANISMS

The rate of atraumatic spontaneous patella dislocation is low in high-level athletes; instability mainly occurs after an initial traumatic dislocation. A non-contact

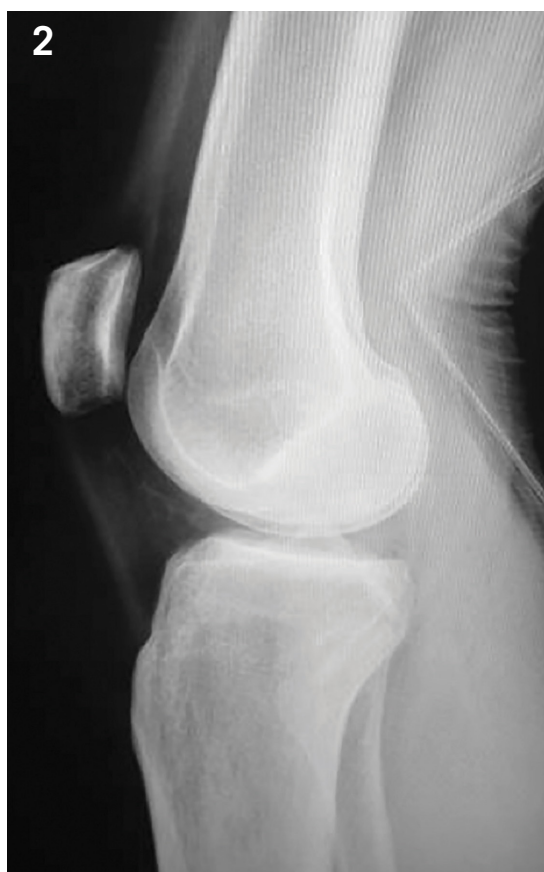
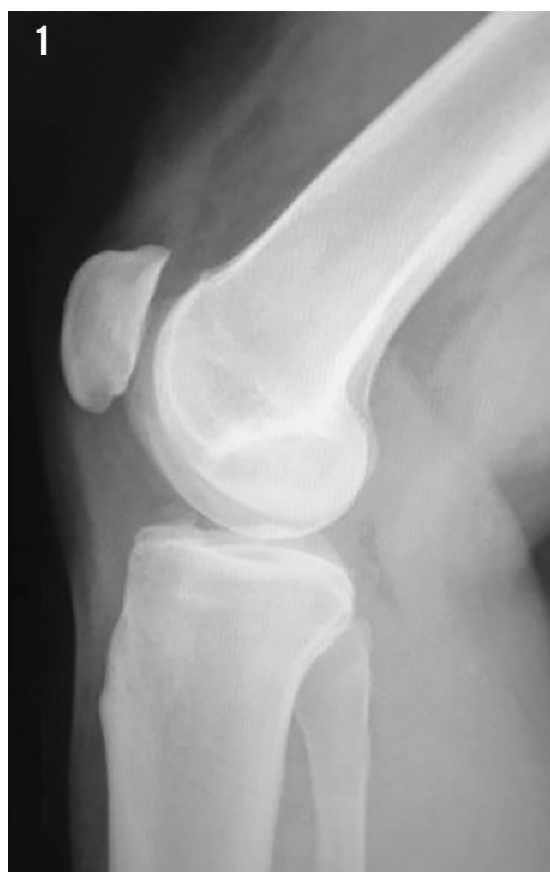
Figure 1: Lateral view of a right knee with a symptomatic patella alta (Caton-Deschamps index of 1.25), at the origin of recurrence of patellofemoral instability.

Figure 2: Lateral view of a right knee showing a trochlear dysplasia type D (according to Dejour's classification⁴), with a crossing sign, a 'double contour' sign and a small supratrochlear spur.

injury mechanism is common, via a valgus flexion, external rotation movement on a fixed foot during pivoting². This mechanism is frequent during soccer and basketball. Contact mechanisms such as player contact are also frequent.

CLINICAL EXAMINATION OF A SUSPECTED PATELLAR DILOCATION

When a patient consults a physician for a patellar dislocation, some elements must be assessed; whether it was indeed a patellar dislocation, the type of mechanism and the onset of instability.

Patient history must focus on four key points:

1. The sequence of patellar dislocation, in particular the necessity of a patellar reduction.
2. The mechanism of the PFI and the energy of the trauma: a non-contact injury mechanism (low-energy trauma) or a contact mechanism (high-energy trauma).
3. The presence of medical history of contralateral PFI.
4. The presence of PFI recurrence after the first episode.

Clinical examination may detect signs of patellar dislocation, such as haemarthrosis – often associated with a medial

subcutaneous haematoma, reflecting a medial patellofemoral ligament (MPFL) injury. This examination also assesses the eventual risk factors of PFI recurrence (genu valgum, J sign, patellar maltracking). The Smillie test is the most important: if a patient has positive apprehension test, the patella will be unstable and disabling with a high risk of PFI recurrence, making a return to sport very difficult. During the early phase, the Smillie test is always painful and gentle manoeuvres are recommended. Clinical tests have moderate utility after patellar dislocation in elite athletes. In any case, the Smillie test is prognostic, indicating the necessity of further surgery and which option is indicated.

WHICH COMPLEMENTARY EXAMS ARE REQUIRED AND WHAT DO YOU ASSESS?

X-rays

Radiological assessment is essential to detect major morphologic risk factors. Lateral view under weight-bearing conditions is crucial to assess patellar height and trochlear dysplasia.

Patellar height

Patellar height is measured on a lateral view at 30° of knee flexion using the Caton-Deschamps index. This index is defined

as the ratio between the patellar length (the distance between the most inferior point of the patella and most anterior tibial articulating surface) and the tendon length (the length of the articular surface of the patella). Patella alta is defined as a ratio between patellar tendon length and patellar articular length ≥ 1.2 (Figure 1). This anatomic characteristic is one of the main risk factors for patellar instability in athletes, particularly in basketball players.

Trochlear dysplasia

On a lateral view of the knee, trochlear dysplasia can be assessed according to the Dejour classification, based on the presence of a crossing sign, a 'double contour' sign or a 'supratrochlear spur' (Figure 2). The crossing sign is the exact point on the lateral X-ray where the groove line crosses the anterior part of the condyles; this occurs only when the trochlea is flat. The supratrochlear spur represents a global prominence of the trochlea, which pushes the patella off the lateral facet when the knee flexes. The 'double contour' sign is the radiographic line ending below the crossing sign and corresponds to the chondral outline of the hypoplastic medial facet on the lateral view.

Other useful parameters such as trochlear depth, the length of the patellar tendon and

knee alignment can be evaluated with other X-rays views.

CT scan

CT scan is the gold standard to assess the tibial tuberosity-trochlear groove (TT-TG) distance and patellar tilt.

TT-TG

The relationship between the tibial tuberosity and the trochlear groove can be calculated by superimposing the section, which best represents the trochlea and the section, which passes through the tibial tuberosity. Two lines, one beginning at the bottom of the groove and another at the centre of the tibial tuberosity, are then subtended perpendicular to the posterior condylar line. A TT-TG >20 mm is considered abnormal and requires a medialisation of the tibial tubercle.

Patellar tilt

The tilt corresponds to the angle drawn between the transverse axis of the patella and the tangent to the posterior femoral condyles. It is measured both with the knee in full extension and at 15° flexion, as well as with the quadriceps relaxed and contracted. A patellar tilt >20° reflects a dysplasia of the vastus medialis and a trochlear dysplasia.

MRI

TT-TG and patellar tilt can also be evaluated on MRI. The advantage of MRI is that chondral damage as a consequence of a traumatic dislocation can also be assessed. The presence of chondral lesions is an indication for an early stabilisation of the patella, in order to avoid new lesions during recurrent dislocations and early patellofemoral osteoarthritis. The presence of loose bodies, or important bone bruises (Figure 3), the status of the MPFL and the site of injury (avulsion or rupture in the ligament) can also be identified on MRI.

IS THERE A PLACE FOR CONSERVATIVE MANAGEMENT AFTER A PATELLA DISLOCATION IN A YOUNG ATHLETE?

In the absence of important anatomic abnormalities, non-operative treatment can be advocated after a first episode, even in elite athletes. The main indications for a non-operative approach are

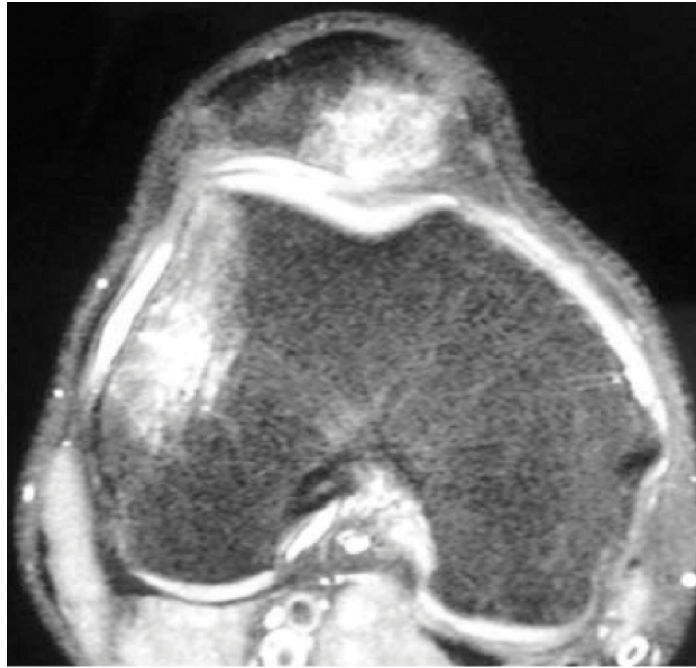


Figure 3: Axial view of a MRI of a right knee after patellar dislocation, showing an important bone bruise of the lateral edge of the trochlea and of the medial patellar ridge.

dislocation associated with a direct blow to the knee, patients with minimal patellar apprehension on physical examination (negative Smillie test), injuries that occur mid-season, and athletes who are involved in sports where bracing is possible.

A safe return to sport after a conservative management implies that the anatomic lesions have healed and the injured lower limb function has adequately recovered to face the demands of sporting activities. Firstly pain, swelling and inflammation resolution should be achieved. Then range of motion must be recovered, followed by recovery of muscle strength, motor patterns and co-ordination. Patients are authorised to return to sports after they regain full passive range of motion, without effusion, and when quadriceps muscle strength is at least 80% of the non-injured limb. Range of motion is usually recovered after 6 weeks. Sport participation is limited during the first 6 months after injury. The athlete should be prepared for the specific loads and demands of their sport.

Of 58 athletes with at least one episode of patellar dislocation treated with functional rehabilitation, Garth et al reported a satisfaction rate of 73%, with 26% of patients suffering recurrent patellar instability at a mean follow-up of 46 months⁵. The natural history of patellar dislocation after non-operative management yields a recurrence rate between 15% and 44% in the general population⁶. Nevertheless, a significant

proportion of those who do not re-dislocate may experience a subjective sensation of instability that may limit athletic performance.

TIMING OF SURGERY: ACUTE OR CHRONIC?

In the general population, after a first episode of patellar dislocation, clinical and imaging check-ups are performed to detect anatomic predisposing factors. During this evaluation, patients are immobilised with a brace to control pain (in extension during the day and at 30° of flexion at night to prevent patella baja). Rehabilitation is started immediately. When range of motion is recovered and the bone bruise has disappeared, surgery can be performed. MPFL reconstruction is always performed, along with associated procedures to address any anatomical abnormalities, as necessary. Acute surgery may be indicated in the case of an intra-articular osteochondral fragment or if there is a femoral or patellar avulsion of the MPFL.

In athletes, early surgery is indicated to avoid PFI recurrence, osteochondral damage and major impact on the level of sports performance. In addition, early operative management after the first episode is justified:

- In patients with associated anatomical abnormalities.
- When the dislocation occurs after minimal trauma.
- In patients with a highly positive apprehension test.



Even after the first episode of patellar dislocation, an injury of the MPFL always occurs⁸. This lesion must therefore be treated systematically in the athletic population



- In case of concurrent osteochondral injury.
- In athletes who play sports with increased PFI risk and in which bracing is not possible.
- In athletes with high-level athletic demands⁷.

In other cases conservative management is preferred.

WHICH SURGICAL TREATMENT IS BEST FOR ATHLETES? HOW DOES THE SURGEON CHOOSE THIS TREATMENT?

The choice is taken according to the anatomic abnormalities, the same as with patients from the general population. All procedures have potential drawbacks that influence sport performance (persistent pain, effusion, stiffness, lack of trust).

Even after the first episode of patellar dislocation, an injury of the MPFL always occurs⁸. This lesion must therefore be treated systematically in the athletic population. In adults, MPFL ruptures are mostly located at the femoral origin or in the middle of the ligament, whereas in adolescents they are more often located at the patellar origin or in the body of ligament. Several therapeutic options for MPFL reconstruction or repair are possible: suture, reinsertion or medial retinacular plication. In acute cases, reinsertion of the avulsed MPFL can

be undertaken on both the femur and the patella. In the general population, MPFL repair has satisfying outcomes and return to the same recreational activities is common⁹. However MPFL repair and medial retinacular plication procedures are less durable than MPFL reconstruction^{9,10}. Apart from adolescents with open epiphyses, MPFL repair is not an option in the athletic population. MPFL reconstruction should be recommended in all athletes operated for patellar dislocation, regardless the location of the rupture. Some authors propose isolated MPFL reconstruction in high-level athletes, even the presence of anatomic risk factors, to avoid more complicated surgical procedures⁸. However, the choice of not addressing significant anatomical abnormalities exposes athletes to disabling episodes of instability or true dislocations, and return to sport may be delayed or prevented entirely.

Patella alta is a common cause of patellar instability, even in athletes, and must be treated with a distalisation of the tibial tubercle. An associated medialisation is indicated for lateralised tibial tubercle with a TT-GT of more than 20 mm.

Trochlear dysplasia is more difficult to treat in athletes. Usually in high-level athletes, this dysplasia is not severe (type A or B, rarely C or D). This moderate dysplasia

must be preserved if possible. In these cases, an MPFL reconstruction with associated transposition can be performed, leaving the native trochlea in place. On the contrary, if the dysplasia is severe, a trochleoplasty must be considered to avoid recurrent patellar dislocations with major disability and osteochondral damage. The outcomes and the rehabilitation of combined procedures are more difficult. The return to sport is uncertain and athletes do not usually return to elite level. However the literature on the issue is lacking, thus preventing a definitive conclusion.

If associated chondral lesions are present, they should be treated. However, return to sport is not always possible, since these have a negative influence on the return to high-impact and high-demand sports activities, especially when they are >2 cm² in area.

WHEN CAN AN ATHLETE RETURN TO SPORT SAFELY AFTER PFI SURGERY?

Rehabilitation is adapted according to the procedures performed. In 2013, the ISAKOS Sports Medicine Committee, led by E. Arendt and F. Kelberine, defined the criteria for a safe return to sport after surgery. If bony surgery has been performed, there should be:

- Complete radiographic healing of bone.
- No complaints of knee pain or instability.
- Complete or nearly complete range of motion.
- No knee effusion.
- Completed neuromuscular training and proprioception recovery.
- Satisfactory core strength and endurance.
- Acceptable control with dynamic activities.
- Limb Symmetry Index >85% on hop tests (especially if resuming pivoting sports).
- Adequate performance with a physiotherapist during sport-specific drills simulating the intensity and movement patterns of the athlete's given sport.
- Athlete showing psychological readiness to return to sport.

Potential anatomical abnormalities are usually present on both knees. Before a return to sport, the contralateral knee should be checked via clinical examination and standard X-ray to assess the risk of contralateral injuries.

The recovery programme and return to sport after surgery is similar to that of post-ACL reconstruction. For strength evaluation, especially in high-demand sports (alpine skiing, football, basketball and handball), patient should reach an LSI (Limb Symmetry Index) of at least 90% before returning to sports.

PFI SURGICAL OUTCOMES IN ATHLETIC THE POPULATION

Successful return to sport implies different parameters which include:

- No early re-injury.
- No further damage to the knee.
- Return to the pre-injury level or higher.
- No disabling pain.
- Patient still playing sport after 5 years.
- No early onset of osteoarthritis¹¹.

The majority of studies on surgical treatment of PFI in athletes report the results of MPFL reconstruction, sometimes with associated tibial tubercle osteotomy. Garth et al³ treated 20 young athletes with recurrent instability after traumatic patellar dislocation with MPFL reconstruction, medialisation of the tibial tubercle and lateral patellar retinaculum release. There was no postoperative recurrent dislocation or instability. All patients improved their activity levels, though without resuming full activity due to persistent pain during full vigorous activity. Krych et al¹² showed 85% return to sport at the same or higher level at a mean follow-up of 8 months, in a series of 39 athletes operated with MPFL reconstruction with associated tibial tubercle osteotomy (41% of patients). Patients, who didn't return to sport, had a positive apprehension test on physical exam, re-injury or risk of long-term problems. Tibial tubercle osteotomy caused delayed return to sport. In a study on 44 tibial tubercle osteotomies performed in athletes and evaluated at a mean follow-up of 46 months, 97% of patients returned to sport at the same or at a higher level, with an International Knee Documentation Committee score of A or B in 95% of cases⁶. Several studies reported less satisfactory results, with return to sport at a lower level even in case of isolated MPFL reconstructions^{13,14}. Feller et al¹⁵ found lower return to sport rates when MPFL reconstruction was combined with another stabilising procedure compared to isolated MPFL reconstruction.



In a study by Ntangiopoulos et al¹⁶, 87% of patients returned to their previous activities after isolated trochleoplasty, but the level of activity was not specified. Nelitz et al reported the outcomes after combined trochleoplasty and MPFL reconstruction for recurrent dislocations in 28 patients with severe trochlear dysplasia¹⁷. At a minimum follow-up of 2 years, one patient returned to sport at a higher level than preoperatively, 16 returned at the same level, and only six patients reported a return to a lower level of activity. Overall, 60 % of patients returned to their previous activities. The major bias of the current literature is that the outcomes are often mixed, with preoperative and postoperative levels of sport not well defined.

CONCLUSION

Patellofemoral instability is mainly secondary to trauma or anatomical abnormalities in young athletes. In adult

athletes, imaging can show anatomical abnormalities, but in high-level athletes they are rarely severe. The treatment can be non-operative or surgical, according to the presence of anatomical abnormalities, associated osteochondral lesions, the number of episodes and the expectations of the athlete. Non-operative treatment exposes patients to a risk of patellofemoral instability and limited athletic performance. Surgical treatment must be adapted to anatomical abnormalities. The prognosis for a return to sport is strongly correlated with the surgical procedures required and the severity of anatomic abnormalities. MPFL reconstruction allows a return to sport in the majority of cases. If an associated procedure is performed concurrently, the return to sport is longer or sometimes not possible at all. Patients with severe anatomic deformities have instability problems from a young age and are rarely high-level athletes.

TAKE-HOME MESSAGES

- Patellofemoral instability is a common injury in the athletic population, in particular among young athletes.
- Before any therapeutic decision, it is essential to assess for associated lesions and anatomical abnormalities with appropriate imaging analysis.
- Conservative treatment is considered after the first episode of PFI when osteochondral damage or anatomical abnormalities are absent.
- Surgical treatment must be limited to the anatomical abnormalities.
- MPFL reconstruction is indicated in almost all athletes with patellar dislocation.
- The outcomes after MPFL reconstruction are satisfying in terms of return to high-level sport.
- Severe anatomical abnormalities, in particular high-grade trochlear dysplasia, are rarely compatible with high-level sports participation.

References

- Mitchell J, Magnussen RA, Collins CL, Currie DW, Best TM, Comstock RD et al. Epidemiology of patellofemoral instability injuries among high school athletes in the United States. *Am J Sports Med* 2015; 43:1676-1682.
- Waterman BR, Belmont PJ Jr, Owens BD. Patellar dislocation in the United States: role of sex, age, race, and athletic participation. *J Knee Surg* 2012; 25:51-57.
- Garth WP Jr, DiChristina DG, Holt G. Delayed proximal repair and distal realignment after patellar dislocation. *Clin Orthop Relat Res* 2000; 377:132-144.
- Dejour D, Le Coultre B. Osteotomies in patello-femoral instabilities. *Sports Med Arthrosc* 2007; 15:39-46.
- Garth WP Jr, Pomphrey M Jr, Merrill K. Functional treatment of patellar dislocation in an athletic population. *Am J Sports Med* 1996; 24:785-791.
- Tjoumakaris FP, Forsythe B, Bradley JP. Patellofemoral instability in athletes: treatment via modified Fulkerson osteotomy and lateral release. *Am J Sports Med* 2010; 38:992-999.
- Hinton RY, Sharma KM. Acute and recurrent patellar instability in the young athlete. *Orthop Clin North Am* 2003; 34:385-396.
- Kuroda Y, Matsushita T, Matsumoto T, Kawakami Y, Kurosaka M, Kuroda R. Bilateral medial patellofemoral ligament reconstruction in high-level athletes. *Knee Surg Sports Traumatol Arthrosc* 2014; 22:2465-2469.
- Matic GT, Magnussen RA, Kolovich GP, Flanigan DC. Return to activity after medial patellofemoral ligament repair or reconstruction. *Arthroscopy* 2014; 30:1018-1025.
- Mountney J, Senavongse W, Amis AA, Thomas NP. Tensile strength of the medial patellofemoral ligament before and after repair or reconstruction. *J Bone Joint Surg Br* 2005; 87:36-40.
- Ménétrey J, Putman S, Gard S. Return to sport after patellar dislocation or following surgery for patellofemoral instability. *Knee Surg Sports Traumatol Arthrosc* 2014; 22:2320-2326.
- Krych AJ, O'Malley MP, Johnson NR, Mohan R, Hewett TE, Stuart MJ et al. Functional testing and return to sport following stabilization surgery for recurrent lateral patellar instability in competitive athletes. *Knee Surg Sports Traumatol Arthrosc* 2016 [Epub ahead of print].
- Ronga M, Oliva F, Longo UG, Testa V, Capasso G, Maffulli N. Isolated medial patellofemoral ligament reconstruction for recurrent patellar dislocation. *Am J Sports Med* 2009; 37:1735-1742.
- Ambrozic B, Novak S. The influence of medial patellofemoral ligament reconstruction on clinical results and sports activity level. *Phys Sportsmed* 2016; 44:133-140.
- Feller JA, Richmond AK, Wasiak J. Medial patellofemoral ligament reconstruction as an isolated or combined procedure for recurrent patellar instability. *Knee Surg Sports Traumatol Arthrosc* 2014; 22:2470-2476.
- Ntagiopoulos PG, Byn P, Dejour D. Midterm results of comprehensive surgical reconstruction including sulcus-deepening trochleoplasty in recurrent patellar dislocations with high-grade trochlear dysplasia. *Am J Sports Med* 2013; 41:998-1004.
- Nelitz M, Dreyhaupt J, Reichel H, Woelfle J, Lippacher S. Anatomic reconstruction of the medial patellofemoral ligament in children and adolescents with open growth plates: surgical technique and clinical outcome. *Am J Sports Med* 2013; 41:58-63.

Cecile Batailler M.D.

Centre Albert Trillat, Orthopedic Surgery
Croix-Rousse Hospital
Lyon, France

Nader Darwich M.D.

HealthPoint, Abu Dhabi Knee & Sports
Medicine Center
Abu Dhabi, United Arab Emirates

Simone Cerciello M.D.

Casa di Cura Villa Betania
Rome, Italy
Marrelli Hospital
Crotone, Italy

Philippe Neyret M.D.

Centre Albert Trillat, Orthopedic Surgery
Croix-Rousse Hospital
Lyon, France

Contact: cecile.batailler@chu-lyon.fr