

OPEN LATARJET PROCEDURE FOR RECURRENT ANTERIOR INSTABILITY OF THE SHOULDER

Operative technique. Personal experience.

– Written by Gilles Walch and Allan Young, France

Glenoid bone loss is commonly observed in anterior instability and varies greatly in both its extent and significance¹⁻³. In 2000, Burkhart and De Beer reported a recurrence rate of 4% following arthroscopic Bankart repair for anterior instability in patients without significant bone deficiency, whereas the rate of recurrence was 67% in the presence of a bone lesion⁴. In the setting of anterior instability with significant bone loss, a Latarjet procedure may be recommended. In 1954, Latarjet (Figure 1) described a coracoid bone block technique to prevent anterior dislocation, suggesting that the horizontal limb of the coracoid process should be fixed to the anteroinferior margin of the glenoid with a screw⁵. Augmentation of the anteroinferior glenoid with this procedure has obvious advantages in cases of glenoid bone loss. However, this 'bone blocking effect' only partially contributes to the stabilising mechanism of the Latarjet procedure. While the precise mechanism is still unknown, the success of the intervention is explained by a triple effect first proposed by Patte⁶:

1. the effect of the conjoint tendon when the arm is abducted and externally rotated, where it acts as a sling on the inferior subscapularis and anteroinferior capsule
2. the 'bony effect', increasing or restoring the glenoid anteroposterior (AP) diameter
3. the effect of repairing the capsule to the stump of coracoacromial ligament (Figure 2).

The technique described here includes a number of modifications from the original. The most notable is the use of two screws instead of one to provide stable fixation of the coracoid and utilisation of a subscapularis splitting approach. Performing the Latarjet procedure through a horizontal split in the subscapularis preserves the continuity of the muscle fibres



the Latarjet procedure can be expected to prevent recurrent anterior instability without the loss of external rotation in more than 98% of cases.



and allows for immediate postoperative range of motion exercises in external rotation. Numerous additional variations of the subscapularis management have been proposed: the position and alignment of the coracoid process, including intra- or extra-articular placement, methods of coracoid fixation, the management of the capsulolabral structures and performing the procedure arthroscopically. Regardless of which specific variations are used, a precise surgical technique is essential to avoid potential complications. With appropriate patient selection, the Latarjet procedure can be expected to prevent recurrent anterior instability without the loss of external rotation in more than 98% of cases⁷.




Figure 1: Michel Latarjet. General surgeon born in Lyon, France (1913–1999).

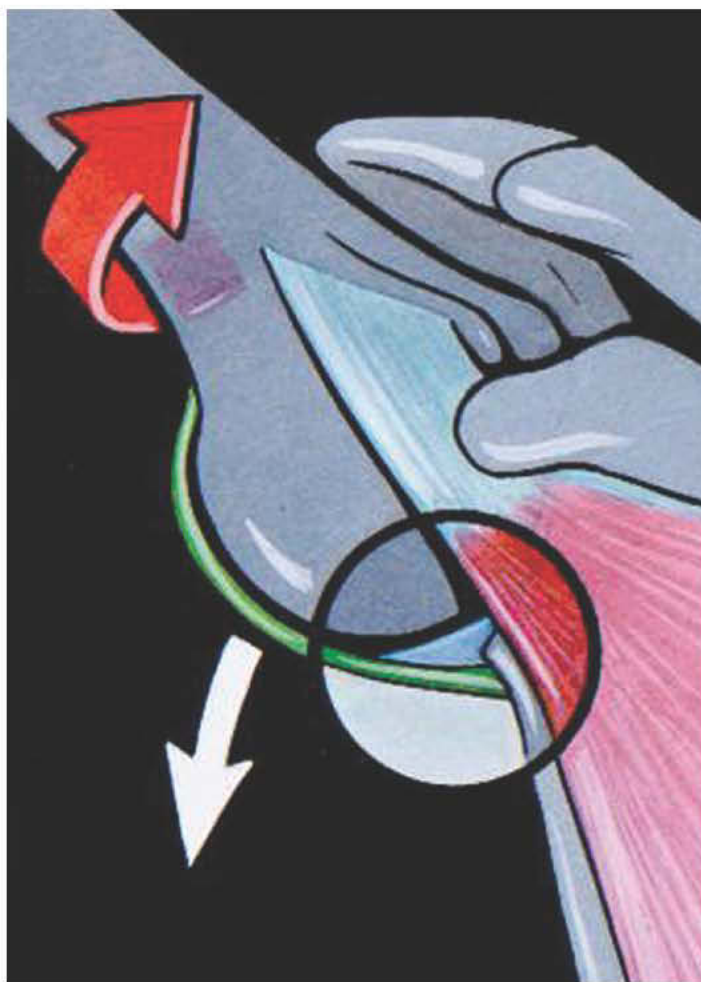


Figure 2a: Normal position of the subscapularis muscle providing no inferior support in provocative position of the shoulder (i.e. abduction and external rotation).

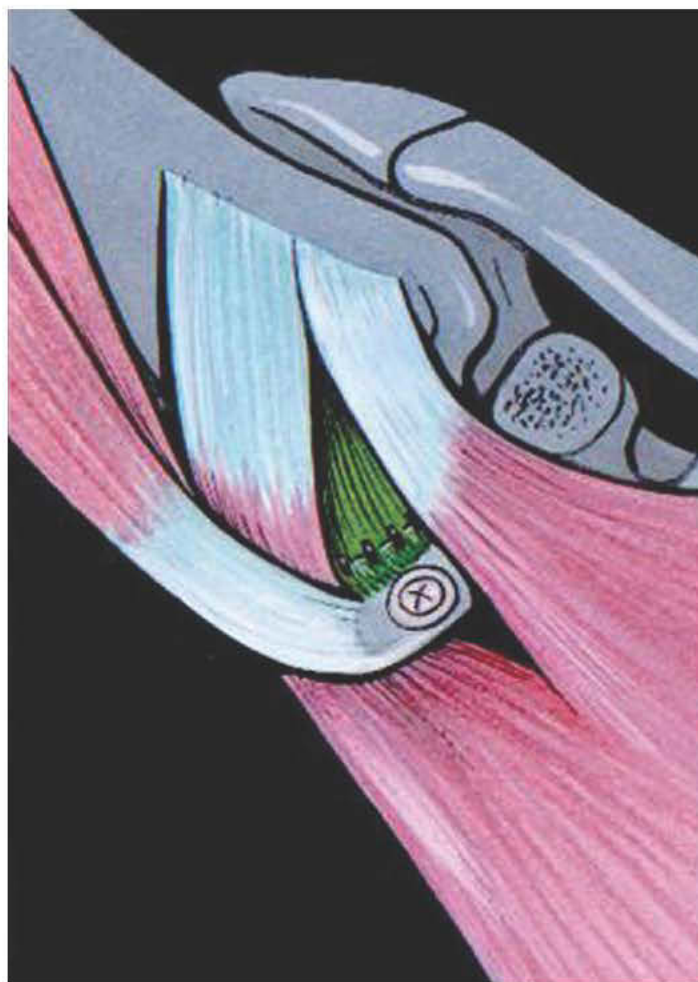


Figure 2b: The inferior displacement of the subscapularis muscle by the conjoint tendon creates a sling beneath the anteroinferior capsule, especially in the abducted, externally rotated position of the arm.



The Latarjet procedure is not recommended in voluntary anterior instability and anterior instability without Bankart lesion

INDICATIONS

Recurrent anterior dislocations or subluxations, with or without hyperlaxity, with or without glenoid bone loss.

CONTRAINDICATIONS

The Latarjet procedure is not recommended in voluntary anterior instability and anterior instability without Bankart lesion, i.e. painful shoulder in the throwing athlete.

EXAMINATION AND RADIOGRAPHIC FINDINGS

Examination findings

- Always assess for axillary nerve injury by examining for sensation in the regimental badge area and motor power of the deltoid.
- Sulcus sign: presence suggests hyperlaxity.
- External rotation with elbow at side: 90 degrees or more defines 'multidirectional constitutional hyperlaxity'.

- Anterior and posterior drawer tests: positive suggests hyperlaxity.
- Anterior apprehension tests (+/- relocation test): positive suggests instability.
- Gagey's hyperabduction test⁸: more than 105 degrees in abduction-internal rotation suggests distension of the inferior glenohumeral ligament (IGHL), and asymmetric difference in abduction of more than 20 degrees implies significant pathologic IGHL distension.

Pearls and pitfalls

The finding of a positive and pain-free anterior drawer test or positive sulcus sign is evidence of constitutional hyperlaxity but not necessarily of instability. Comparison should be made with the asymptomatic shoulder, and usually the tests for hyperlaxity are bilaterally positive. Clinical examination should aim to differentiate general hyperlaxity from pathological laxity associated with true instability (to identify

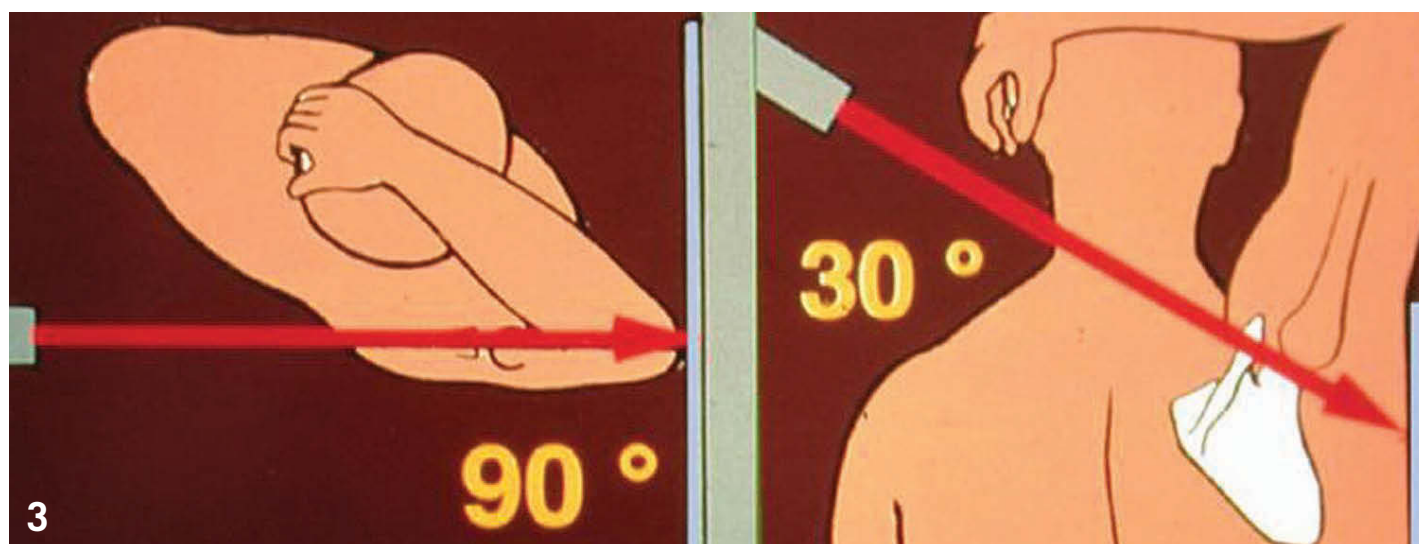


Figure 3: Technique of the Bernageau glenoid profile views obtain with fluoroscopic control.

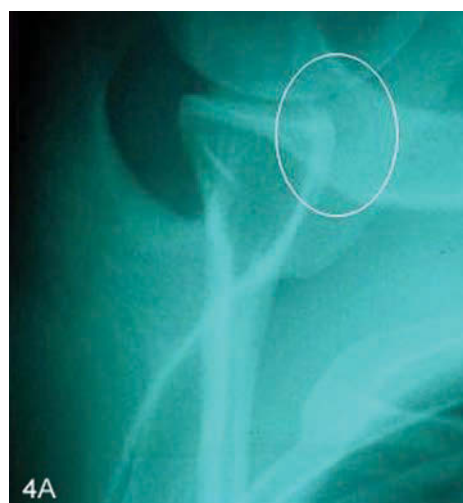

Figure 4a: Osseous lesion associated with anterior instability, demonstrating blunting of the anterior inferior glenoid.

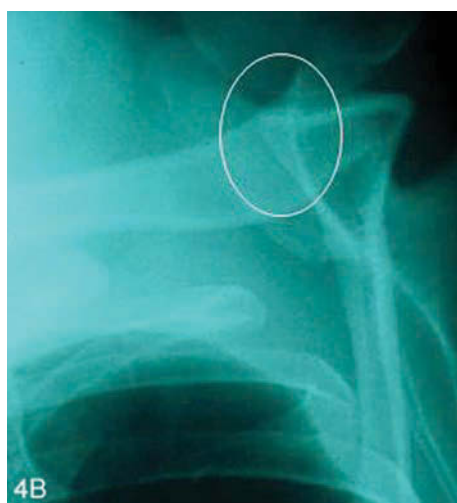

Figure 4b: Normal contralateral glenoid profile with maintenance of anterior 'triangle' appearance.

Figure 5 (over page): Hohmann retractor is placed over coracoid in the deltopectoral space and add exposure to the coracoacromial ligament incision along coracoacromial ligament incised 1 cm from coracoid insertion (arm in externally rotated position).

pathological laxity of the IGHL specifically, looking for significant asymmetry compared with the asymptomatic side, we have found the Gagey sign most useful).

Radiographic findings

Plain radiographs should include AP views in neutral, internal and external rotation, as well as bilateral profile views of the glenoid for comparison, as described by Bernageau⁹ (Figures 3 and 4).

Pearl

Radiographs should preferably be taken under fluoroscopic control. Using this method, a glenoid rim lesion will be apparent in 85% of anterior instability cases and a Hill-Sachs lesion will be visualised in 75% of cases^{1,2}.

Computed tomography (CT) or magnetic resonance imaging (MRI) scans are not part of our standard preoperative planning but may assist in the diagnosis in cases of subtle instability. CT scanning may be valuable

if concern exists regarding a significant glenoid bony lesion.

CT arthrogram (or MRI) is recommended if concern exists regarding the possibility of a concomitant rotator cuff tear or in case of doubt regarding the diagnosis of instability.

DESCRIPTION OF SURGICAL TECHNIQUES

Patient positioning

The patient is placed in a beach-chair position and the arm is draped free to allow intraoperative abduction and external rotation.

Surgical exposure

A deltopectoral approach is used. The skin incision is vertical from the tip of the coracoid extending 4 to 5 cm towards the axillary fold. In cases where improved cosmesis is desirable (i.e. young females), an incision as small as 3 cm can be used. The cephalic vein is taken laterally and its large medial branch is ligated. A self-retaining retractor is used to maintain exposure

between the deltoid and pectoralis major. The arm is placed in abduction and external rotation and a Hohmann retractor is placed over the top of the coracoid process (Figure 5).

Procedure

Step 1: Coracoid osteotomy and preparation

The arm is placed in external rotation with some abduction to expose the coracoacromial ligament (CAL), which is incised 1 cm from its coracoid attachment (Figure 6). The coracohumeral ligament, found beneath the CAL, is then released.

Subsequently, the arm is adducted and internally rotated to improve exposure on the medial side of the coracoid. The pectoralis minor is released from the coracoid, taking care not to continue release past the tip of the coracoid and damage the remaining blood supply to the coracoid. A periosteal elevator is used to remove any soft tissue from the under-surface of the coracoid. The 'knee' of the coracoids, which

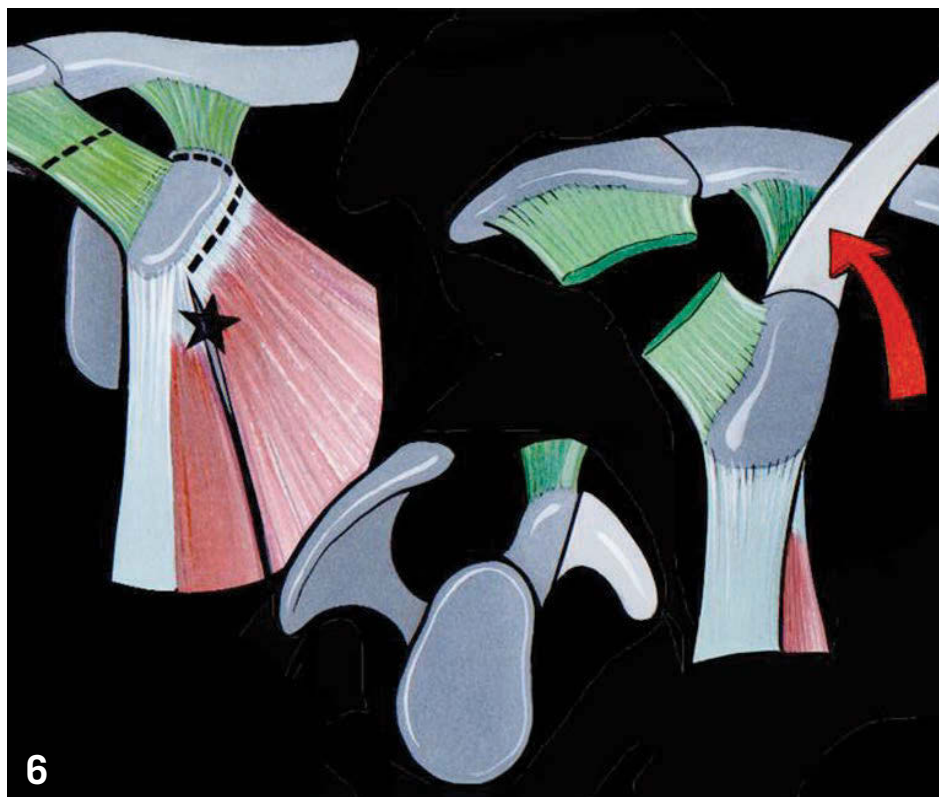
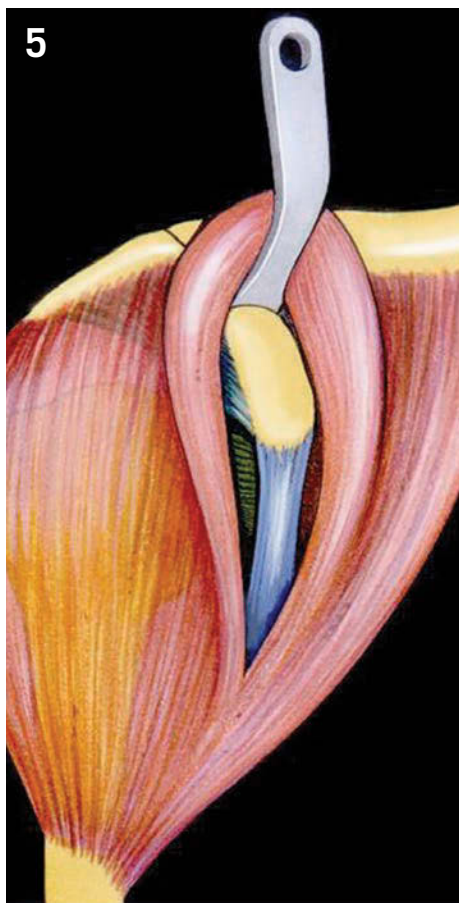


Figure 6: Incision along coracoacromial ligament incised 1 cm from coracoid insertion. Following release of the pectoralis minor, the osteotomy is performed at the 'knee' of the coracoid (i.e. distal to the coracoclavicular ligaments).

is the site of the osteotomy, should now be visible. This typically allows for the harvesting of a 2.5 to 3 cm coracoid fragment (Figure 6). Using a 90-degree oscillating saw, the osteotomy is made from medial to lateral. It is important to make sure that the osteotomy is performed perpendicular to the coracoid process to prevent accidental extension into the glenoid articular surface. If required, levering on the fragment with an osteotome can assist in completing the osteotomy. The arm is again placed in an abducted externally rotated position and the coracoid fragment grasped with toothed forceps. Any remaining coracohumeral ligament attachments are released.

The arm is returned to the neutral position and the coracoid is delivered onto a swab at the inferior aspect of the wound. The soft tissue is removed from the inferior surface of the coracoid using a scalpel, taking care to preserve the CAL stump. The oscillating saw is then used to decorticate the inferior coracoid surface, exposing a broad, flat cancellous bed to optimise graft healing. Typically, there is a spike of bone from the vertical portion of the coracoid at the osteotomised end of the graft, which needs to be removed. An osteotome is

placed beneath the coracoid to protect the skin, and two drill holes are made using a 3.2 mm drill. The holes are placed in the central axis of the coracoid and about 1 cm apart (Figure 7). Electrocautery is used to clear any soft tissue from the holes, and the drilling is repeated in the opposite direction to complete the tunnels.

The swab protecting the skin is removed and the arm externally rotated with the elbow by the side. The upper lateral border of the conjoint tendon is released for about 5 cm using Mayo scissors. The coracoid is then pushed beneath the pectoralis major, exposing the subscapularis muscle.

Step 2: Glenoid exposure

With the arm by the side and externally rotated, the subscapularis is exposed. The superior and inferior borders of the muscle should be identified. The location of the subscapularis split is at the junction of the superior two thirds and the inferior one third (Figure 8). In patients with constitutional hyperlaxity noted in the preoperative examination, the split is performed in the middle of the subscapularis to maximise the effect of the conjoint tendon sling. The subscapularis muscle is then split in

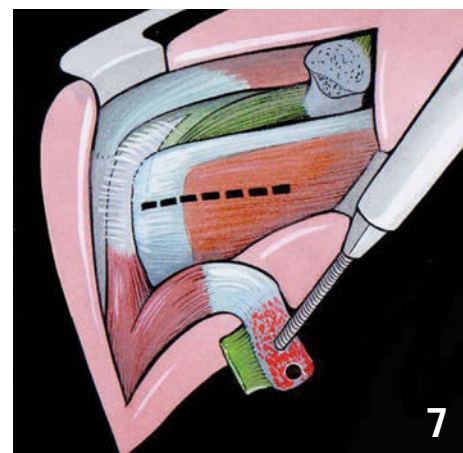


Figure 7: Two holes are made in the graft using a 3.2 mm drill bit, 1 cm apart.

line with its fibres using Mayo scissors. The scissors are pushed between the fibres as far as the capsule, then opened perpendicular to the direction of the muscle fibres. Maintaining the scissors in the open position, with the capsule visualised, a swab is pushed in a superior and medial direction into the subscapular fossa. This acts to free up the subscapularis from the underlying capsule, significantly improving the exposure. A Hohmann retractor is then placed on the swab in the subscapularis fossa.

Using a curved retractor, such as a Bennett retractor, on the inferior part of the subscapularis, the lateral aspect of the split is extended to the lesser tuberosity with a scalpel. The joint line should now be more easily visualised. A 1 to 2 cm vertical incision in the capsule is made at the level of the joint line, allowing placement of a retractor into the glenohumeral joint. We prefer a Trillat retractor (Axone Medical, Lyon, France) due to its low profile; however, a Fukuda-type retractor or similar can also be used. Superior exposure is improved by placing a 4 mm Steinman pin as high as possible into the superior scapular neck. The medial Hohmann retractor is exchanged for a link retractor and placed as medial as possible on the scapula neck.

A small Hohmann retractor is placed inferiorly between the capsule on the inferior neck and the inferior part of the subscapularis, exposing the '6 o'clock' position on the glenoid. The anteroinferior aspect of the glenoid should now be completely exposed.

Step 3: Glenoid preparation and coracoid fixation

The anteroinferior labrum and periosteum are incised with electrocautery, commencing at the '5 o'clock' position in a right shoulder ('7 o'clock' in a left shoulder) and continuing medially on to the glenoid for about 2 cm. The incision is then directed vertically for a distance of 2 to 3 cm and, lastly, turned laterally to complete the incision by dividing the labrum again, this time at the '2 o'clock' position ('10 o'clock' in a left shoulder). An osteotome is used to elevate this labral-periosteal flap from the glenoid in a lateral to medial direction, facilitated by the frequent presence of a Bankart lesion. An osteotome is used to decorticate the anteroinferior surface of the glenoid. The aim is to create a flat surface on which the coracoid graft can be placed (Figure 9).

Using the 3.2 mm drill, the first hole is created at the '5 o'clock' position in the glenoid, sufficiently medial that the coracoid will not overhang the glenoid. This distance is typically 7 mm, but can vary depending on the coracoid morphology. The drill is directed parallel to the glenoid articular surface and drilling continued until passing through the posterior cortex.

The coracoid is now retrieved from its position under the pectoralis major

and grasped at the cut end in a medial-lateral fashion. A 35-mm 4.5-mm partially threaded malleolar screw is fully inserted into the inferior hole in the coracoid graft (tendinous end). Although this is typically the correct length of the inferior screw, it can be exchanged later, if required, following placement of the second screw.

The screw is then placed into the drilled hole in the glenoid and tightened into position, ensuring that the coracoid is in the requested position, parallel to the articular margin of the glenoid with no overhang. Ideally, the graft is positioned flush; however, a slightly medial position (1 to 2 mm) is acceptable. A lateral overhanging of the coracoid should not be accepted, as this may lead to progressive degenerative joint disease.

When the position of the coracoid is parallel to the glenoid, the second hole is drilled with a 3.2 mm drill utilising the hole already made in the coracoid. Again, drilling is directed parallel to the glenoid surface and continued through the posterior cortex. Rotation of the coracoid is controlled using heavy forceps. The depth of the tunnel is measured with a depth gauge, and a malleolar screw of the correct size is inserted. Again, this is typically 35 mm (range 30 to 40 mm) in length. Both screws are tightened alternately using a 'two finger' technique. Aggressive over-tightening should be avoided as it can lead to fracture of the coracoid. The position of the coracoid is checked one final time. If any lateral overhang of the coracoid is observed, it should be removed with a bone rongeur or a high-speed bur.

The capsule is repaired to the stump of the CAL using a Number 1 absorbable braided suture (Figure 10). It is important to perform this repair with the arm position in full external rotation with the elbow by the side. This enables immediate postoperative range-of-motion exercises in external rotation. Two sutures are sufficient for the capsular repair, which is in a direct medial to lateral direction. We have found no benefit from attempting to combine a capsular shift with this repair.

The swab is removed from the subscapular fossa and all retractors removed. We do not repair the split in the subscapularis muscle. The wound is closed in layers. A drain is typically not used, unless excessive bleeding is noted.

Intraoperative complications

Complications specific to this procedure are usually caused by technical error.

Tips and tricks: avoiding technical errors

Coracoid fracture is avoided by:

- using a 'two finger' screwdriver tightening technique
- not drilling with larger than 3.2 mm drills, such as is required if attempting to use a 4.5 mm cortical screw, which necessitates drilling a gliding hole in the coracoid with 4.5 mm drill for compression
- checking the final position of the coracoid by visualisation and palpation with the tips of a pair of closed Mayo scissors. If overhanging is present, the position of the coracoid should be changed or the coracoid trimmed with a bone rongeur or high-speed bur.

VARIATIONS AND UNUSUAL SITUATIONS

A number of variations have been described for the Latarjet procedure. These primarily relate to the surgical approach, position and fixation of the coracoid and the management of the capsulolabral tissues.

Surgical approach

The original description of this procedure by Latarjet involved sectioning of the subscapularis. A number of other variations exist regarding the approach to the subscapularis. We recommend preserving the integrity of the subscapularis by performing a split.

Coracoid process

The coracoid can be positioned in the 'lying' position as we have suggested or in the 'standing' position. We recommend using the lying position to allow placement of two screws for stable fixation and to increase the contact surface area for union. A variation of the lying position has been described in which the coracoid is rotated 90 degrees to match the radius of curvature of the glenoid¹⁰.

Fixation

The coracoid can be fixed with either one or two screws, with or without washers. We have recently started using bioabsorbable screws for fixation. While our preliminary results are encouraging and there have been no complications to date, we cannot recommend their use now because more follow-up is needed.

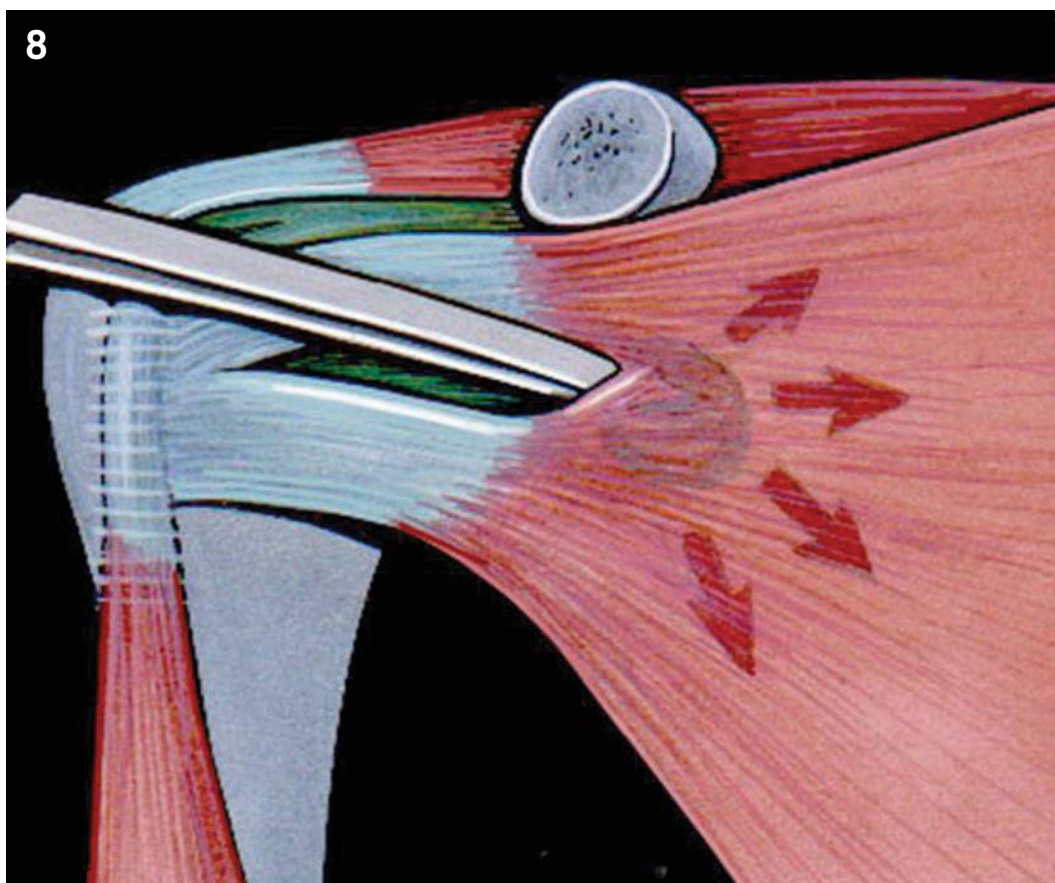

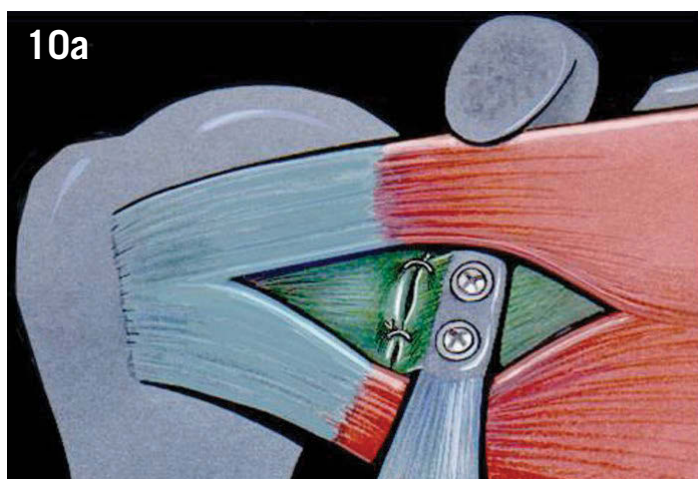
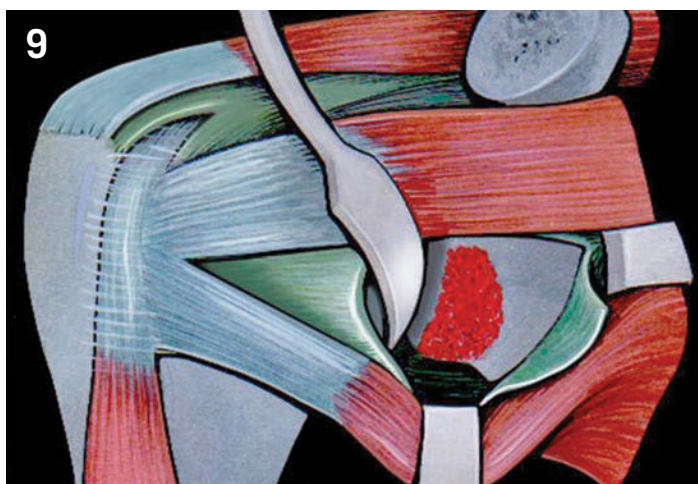


Figure 8: Division of the subscapularis muscle at the junction of the upper two-thirds and inferior one-third in line with its fibres.

Figure 9: Vertical capsulotomy is performed at the level of the glenohumeral joint, just sufficient to allow placement of a Trillat retractor. Completed exposure of the anterior inferior glenoid with toothed retractor medially, Trillat retractor laterally and Hohmann retractor inferiorly. Incision for removal of the labrum and periosteum and decortication of the native glenoid.

Figure 10a: Anterior view of final reconstruction following repair of capsule to coracoacromial ligament remnant.

Figure 10b: Sagittal view showing that the inferior part of the subscapularis muscle is trapped under and posterior to the conjoint tendon.



	NUMBER OF PROCEDURES PERFORMED	FOLLOW-UP DURATION	REDISLOCATION RATE
ALLAIN (1998) ¹⁴	95	14 years	0%
BURKHART (2007) ¹³	102	5 years	3.9%
HOVELIUS (1983) ¹⁹	112	2.5 years	6%
HOVELIUS (2004) ¹⁵	118	15 years	3.4
SINGER (1995) ²⁰	14	20 years	0%
WALCH (1991) ¹²	354	3 years	1%
WALCH (2000) ⁷	160	3 years	1%

Table 1: Recurrence rates in different variations of the Latarjet procedure

Capsulolabral tissues

Although we prefer to place the coracoid in an 'intra-articular' position, it can be positioned extra-articularly. In this situation, either the coracoid can be fixed to the glenoid without disturbing the capsulolabral pathology or the capsulolabral tissues can be elevated and repaired to the glenoid articular margin as per a traditional Bankart procedure.

POSTOPERATIVE CARE

The patient is placed in a simple sling for a period of two weeks for comfort. This also encourages rest, reducing the risk of haematoma formation. Rehabilitation commences on the first postoperative day with active motion of fingers, hand and elbow. Passive range of motion of the shoulder also starts on the first postoperative day, either with the assistance of the other arm in the bed or with pendulum-type exercises. Standard postoperative rehabilitation protocol is advised for three months. Return to full sports activity (including contact sports) is allowed at three months. Radiographs are obtained on the first postoperative day and at three months (Figure 11).

POSTOPERATIVE COMPLICATIONS

- Haematoma can be avoided by achieving haemostasis prior to wound closure and using a drain. Additionally, the arm is rested in a sling for two weeks postoperatively.
- Infection: rare.
- Coracoid non-union: to encourage bone

healing, we recommend:

- preparing flat surfaces and cancellous bone exposure in both the coracoids and glenoid
- using a long piece of coracoid, typically 2.5 to 3 cm
- placing the coracoid graft in the 'lying position' and using the inferior surface to increase the surface area for union
- using stable fixation with two bicortical compression screws. This complication has not been shown to correlate with a poor result⁷.
- Stiffness and loss of external rotation: exceedingly rare following this procedure with the use of a subscapularis splitting approach. To avoid loss of external rotation, it is important to repair the capsule to the CAL stump with the arm positioned in external rotation with the elbow by the side.
- Degenerative joint disease: avoid lateral overhang of the coracoid, which has been shown to be associated with development of osteoarthritis^{14,17}. Also, avoid intra-articular screw placement and we recommend not using washers.
- Subscapularis fatty infiltration: associated with dividing the subscapularis and can be avoided by using a horizontal subscapularis splitting approach.
- Recurrence is demonstrated to be about 1%, in our experience⁷. In the absence of complications, such as fracture of the coracoid process, the recurrences we have observed were related to voluntary subluxators or in cases of epileptic

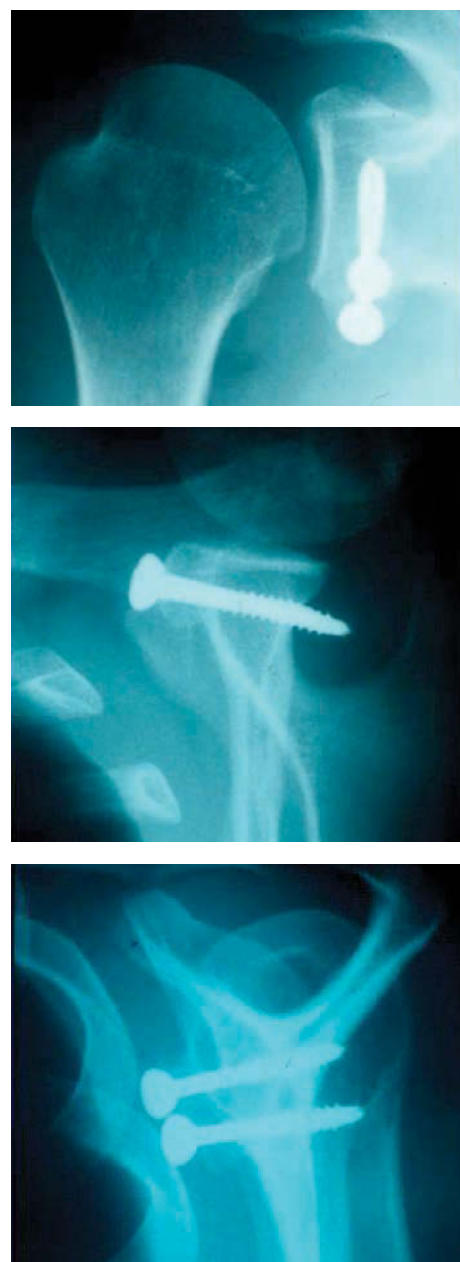

Figure 11: Postoperative radiographs (True AP-A, lateral-B and Bernageau views-C) demonstrating correct placement of the graft with no lateral overhang and bicortical screw fixation.

seizures when the neurologic treatment was not efficient or 'stable'.

- Recurrence after a Latarjet procedure can be successfully treated with a modified Eden-Hybinette procedure¹¹.

PROGNOSIS AND OUTCOMES

In more than 2500 cases performed until today, our recurrent instability rate is 1%^{7,12}. Additionally, 83% of our patients have been able to return to sports at their pre-injury level, and 98% rated their result as excellent or good. Objectively, using the modified Rowe score, 76% of patients

achieved an excellent or good result. Others have reported similarly low recurrence rates using different variations of the Latarjet procedure^{13-16,18-20} (Table 1). Recently, Burkhart and De Beer reported their results using a modified Latarjet procedure in patients with anterior instability and significant bone loss¹³. They reported four recurrent dislocations out of 102 patients, all occurring in the early postoperative period because the patients did not respect standard postoperative protocol.

TIPS AND TRICKS

Avoid loss of external rotation

We have not found a significant loss of external rotation in our patients following the Latarjet procedure, as reported by others¹³⁻¹⁵. The key differences in our

technique, which avoid the loss of motion postoperatively are:

1. use of a subscapularis splitting approach
2. repair of the capsule to the CAL stump with the arm in external rotation
3. immediate postoperative external rotation exercises.

Arthritis is associated with shoulder dislocation per se and not with well-performed operative repairs¹¹. There is no difference in postoperative arthritis following coracoid transfer and open anterior soft tissue procedures¹⁷. Hovelius reported 15-year results following the Latarjet procedure and found 14% of patients had moderate or severe

osteoarthritis (OA), commenting that no other long-term study of the Bankart demonstrated less OA¹⁸. The occurrence of postoperative shoulder arthritis is related to pre-existing factors (e.g. increased age at the time of first dislocation, increased age at the time of surgery and presence of arthritis before surgery) and preventable factors (i.e. lateral overhang of coracoid).

CONCLUSION

The Latarjet procedure is a safe and reliable technique for treating recurrent anterior instability. It is particularly useful for anterior instability with associated glenoid bone loss. Most of the reported complications associated with this procedure can be avoided with proper patient selection and a systematic surgical technique.

References

1. Edwards TB, Boulahia A, Walch G. Radiographic analysis of bone defects in chronic anterior shoulder instability. *Arthroscopy* 2003; 19:732-739.
2. Edwards TB, Walch G. The Latarjet procedure for recurrent anterior shoulder instability: rationale and technique. *Operative Techniques in Sports Medicine* 2002; 10:25-32.
3. Itoi E, Lee SB, Berglund LJ, Berge LL, An KN. The effect of a glenoid defect on antero-inferior stability of the shoulder after Bankart repair: a cadaveric study. *J Bone Joint Surg Am* 2000; 82:35-46.
4. Burkhart SS, De Beer JF. Traumatic glenohumeral bone defects and their relationship to failure of arthroscopic Bankart repairs: significance of the inverted-pear glenoid and the humeral engaging Hill-Sachs lesion. *Arthroscopy* 2000; 16:677-694.
5. Latarjet M. [Treatment of recurrent dislocation of the shoulder]. *Lyon Chir* 1954; 49:994-1003.
6. Patte D, Debeyre J. [Recurrent dislocation of the shoulder]. *Encycl Med Chir Paris-Technique chirurgicale Orthopedie* 1980; 44265:4-4-02.
7. Walch G, Boileau P. Latarjet-Bristow procedure for recurrent anterior instability. *Techniques in shoulder and elbow surgery* 2000; 1:256-261.
8. Gagey OJ, Gagey N. The hyperabduction test. *J Bone Joint Surg Br* 2001; 83:69-74.
9. Bernageau J, Patte D, Debeyre J, Ferrane J. [Value of the glenoid profile in recurrent luxations of the shoulder]. *Rev Chir Orthop Reparatrice Appar Mot* 1976; 62:142-147.
10. De Beer J, Burkhart SS, Roberts CP, van Rooyen K, Cresswell T, du Toit DF. The Congruent-Arc Latarjet. *Techniques in Shoulder and Elbow Surgery* 2009; 10:62-67.
11. Lunn JV, Castellano-Rosa J, Walch G. Recurrent anterior dislocation after the Latarjet procedure: outcome after revision using a modified Eden-Hybinette operation. *J Shoulder Elbow Surg* 2008; 17:744-750.
12. Walch G. [The anterior recurrent dislocation of the shoulder]. *Rev Chir Orthop* 1991; 77:177-192.
13. Burkhart SS, De Beer JF, Barth JR, Cresswell T, Roberts C, Richards DP. Results of modified Latarjet reconstruction in patients with antero-inferior instability and significant bone loss. *Arthroscopy* 2007; 23:1033-1041.
14. Allain J, Goutallier D, Glorion, C. Long-term results of the Latarjet procedure for the treatment of anterior instability of the shoulder. *J Bone Joint Surg Am* 1998; 80:841-852.
15. Hovelius L, Sandström B, Sundgren K, Saebo M. One hundred eighteen Bristow-Latarjet repairs for recurrent anterior dislocation of the shoulder prospectively followed for fifteen years: study I – clinical results. *J Shoulder Elbow Surg* 2004; 13:509-516.
16. Hovelius L, Saeboe M. Neer Award 2008: arthropathy after primary anterior shoulder dislocation – 223 shoulders prospectively followed up for twenty-five years. *J Shoulder Elbow Surg* 2009; 18:339-347.
17. Buscayret F, Edwards TB, Szabo I, Adeleine P, Coudane H, Walch G. Glenohumeral arthrosis in anterior instability before and after surgical treatment: incidence and contributing factors. *Am J Sports Med* 2004; 32:1165-1172.
18. Hovelius L, Sandström B, Saebo M. One hundred eighteen Bristow-Latarjet repairs for recurrent anterior dislocation of the shoulder prospectively followed for fifteen years: study II – the evolution of dislocation arthropathy. *J Shoulder Elbow Surg* 2006; 15:279-289.
19. Hovelius L, Akemark C, Albrektsson B, Berg E, Körner L, Lundberg B, Wredmark T. Bristow-Latarjet procedure for recurrent anterior dislocation of the shoulder. A 2–5 year follow-up study on the results of 112 cases. *Acta Orthop Scand* 1983; 54: 284-290.
20. Singer GC, Kirkland PM, Emery RJ. Coracoid transposition for recurrent anterior instability of the shoulder. A 20-year follow-up study. *J Bone Joint Surg Br* 1995; 77:73-76.

Gilles Walch, M.D.

Allan Young, M.D.

Centre Orthopédique Santy
Lyon, France

Contact: walch.gilles@wanadoo.fr