

# CHRONIC ATHLETIC GROIN PAIN

## One Surgeon's Approach

– Written by John Garvey, Australia

Chronic athletic groin pain is a common symptom in football players in all codes. Chronic groin pain includes multiple interdependent pathologies. The common coexisting pathologies found on ultrasound and at surgery are posterior inguinal canal deficiency, osteitis pubis and conjoint and adductor tendinopathy. Overuse in sports involving kicking, sprinting and change of direction are implicated as the cause of athletic pubalgia. Various operations in the inguinal region have been proposed, including open repair, mesh repair, laparoscopic repair and inguinal canal release. The author supports the 'complex interdependent model' of Orchard that involves multiple pathologies that usually coexist and result in a common clinical presentation that usually require a similar common operation for management. Surgical management takes place only after failed conservative treatment.

### INTRODUCTION

Athletic groin pain (athletic pubalgia) is one of the least understood and poorly explained injuries in sports medicine. There is no consensus on diagnosis, pathophysiology or management. Yet in football, it is a common diagnostic and management challenge for the sports physician and in any one football team there can be two or three players per season carrying a groin injury anticipating surgery. A most comprehensive review on the pathophysiology of chronic athletic groin pain including thorough literature

search was performed by Dr John Orchard and colleagues in 2000<sup>1</sup>. The majority of patients with chronic groin pain have concurrent symptoms in both the inguinal and the adductor region. The site of pain is well-localised to the pubic tubercle and adductor longus insertion and recurs once vigorous sporting activity is resumed. The term 'athletic pubalgia' is defined by Orchard et al as groin pain that occurs in athletes who have no obvious hernia and no other non-pubic aetiology for groin pain. The typical pattern of injury encountered includes adductor tendinopathy, conjoint insertion tendinopathy, osteitis pubis, sports (occult, incipient) hernia, peripheral nerve entrapment and acetabular labral tear of the hip joint. Risk factors include adductor muscle imbalance, reduced hip joint range of motion, delayed core stability, previous groin injury and pelvic instability.

### CONTROLLED TRIALS

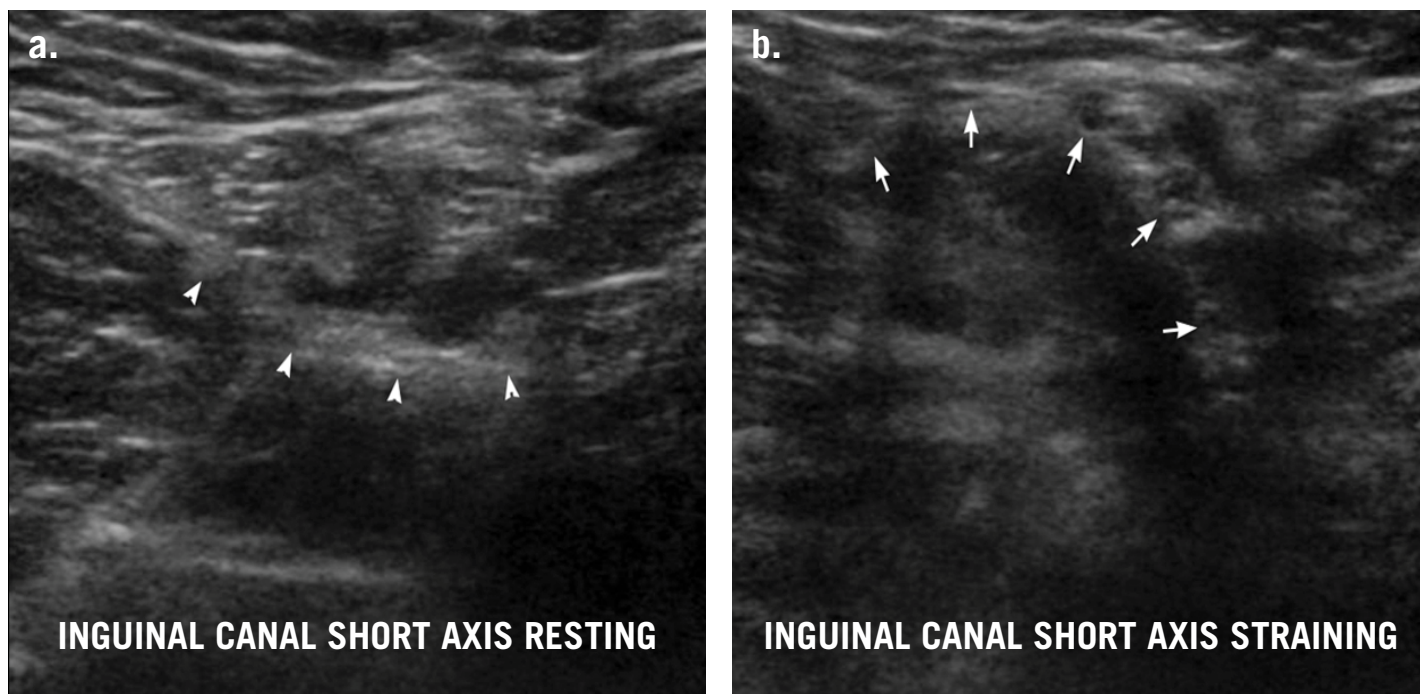
There are only two randomised control trials comparing surgery with conservative treatment. The first randomised control study was carried out by Ekstrand and Ringborg in Sweden<sup>2</sup> and comprised 66 soccer players with groin pain randomised into three conservative groups and one intervention group:

1. Individual training
2. Anti-inflammatory treatment
3. Physical therapy
4. Open operative surgical repair.

They found that only the open operative group showed any significant



**Above:** Chronic athletic groin pain is common in football players of all codes



**Figure 1:** Sports hernia. Two separate cine frames from a dynamic short-axis ultrasound examination of inguinal canal show (a) the normal resting contour of posterior inguinal wall (arrowheads) and (b) the abnormal convex anterior bulge of incipient direct inguinal hernia (arrows). *Image courtesy of Dr J.W. Read*

improvement of symptoms. In a more recent study, Paajanen et al<sup>3</sup> randomised 60 patients with suspected sports hernia into laparoscopic totally extraperitoneal (TEP) repair or two months of physiotherapy, corticosteroid injections and oral anti-inflammatory agents. Ninety percent of patients returned to sport activity after three months in the operated group compared to 27% in the non-operative group. After six months, seven of the control group crossed over into the operation group because of persistent pain. At 12 months, two thirds of the non-operated group had stopped playing their sport of choice or continued to have disabling symptoms at one year's follow-up.

#### SPORTS HERNIA

Sports hernia (disruption of the inguinal canal muscle that does not produce a visible or palpable herniation) is the most common single diagnosis and requires ultrasound or computed tomography (CT) for preoperative diagnosis. There is no published evidence that a sports hernia can be palpated clinically. Abnormal results on ultrasound correlates with groin pain, but approximately 20% of asymptomatic footballers will have sports hernia (although the number studied [5/26] was small)<sup>4</sup>. At surgery, a deficiency in the posterior wall

of the inguinal canal medial to the inferior epigastric artery in Hesselbach's triangle is the most common pathological finding. In addition to being seen at surgery, this can be imaged by ultrasound and CT scan.

#### OTHER COEXISTING PATHOLOGIES

Multiple coexisting diagnoses have been described in 27 to 95% of subjects. A split in the conjoint tendon can be imaged but only seen in about 5 to 10% of patients at surgery and is better imaged by ultrasound.

Adductor insertional tendinopathy has been likened to tennis elbow (David Lloyd, personal communication). Osteitis pubis usually coexists with adductor tendinopathy.

Clinical imaging and operative findings provide evidence of a single unifying pattern: sports hernia, conjoint tendinopathy, adductor tendinopathy, osteitis pubis, peripheral nerve entrapment and pelvic instability as multiple coexisting pathologies which constitute the syndrome of groin disruption injury (GDI). Studies are inconclusive as to what contribution each of these entities makes to the symptom of pubalgia in sports medicine. Rarely does a 'single-diagnosis' explain many cases of pubalgia. The multiple coexisting pathology concept of athletic groin pain implicating overload of the bone tendon complex gives a more functional approach to chronic

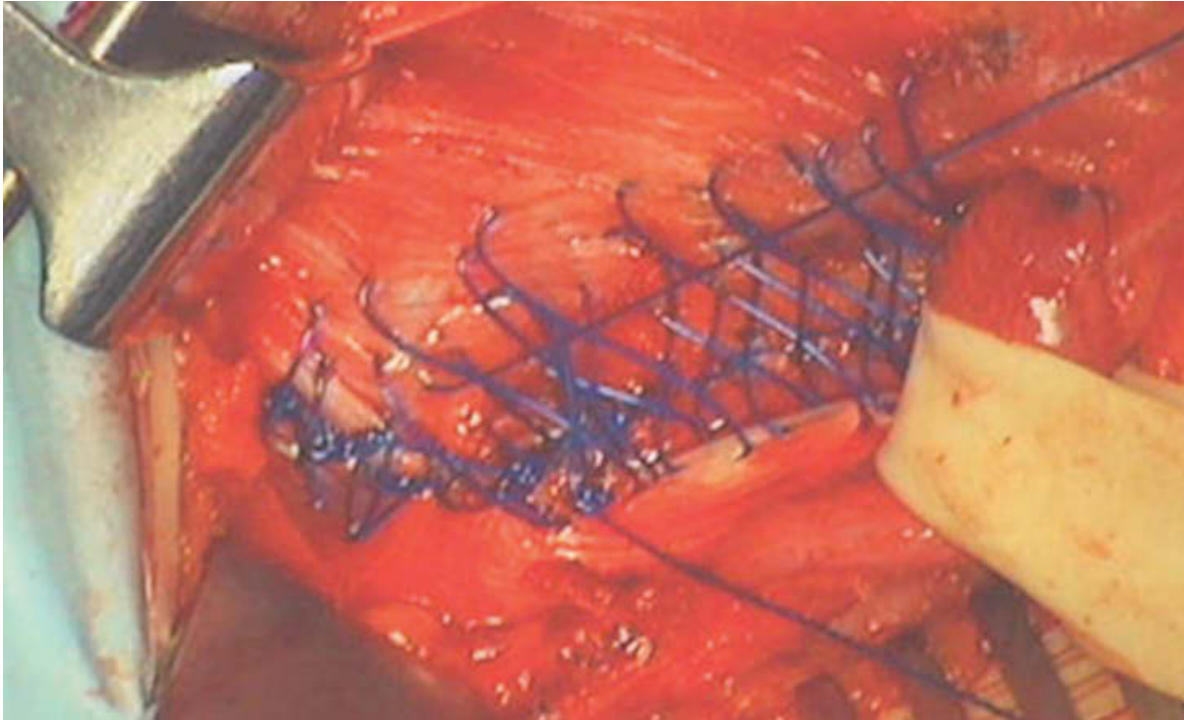
groin pain. In the majority of patients, once non-pubic causes of groin pain have been eliminated by history, physical examination and basic investigations, then the pathological syndrome of adductor tendinopathy, bone stress, weakness of the posterior wall of the inguinal canal and a conjoint tendinopathy can be presumed to be coexisting. Conservative management only has a role if there is no sports hernia present because if sports hernia exists, conservative management will be futile and the player will have lost a substantial amount of playing time. There is not a shred of evidence to support the theory that sports hernia can be corrected by physiotherapy.

Nerve entrapment, either/both in the inguinal canal and in the adductor compartment, may contribute to the cause of pain in sports hernia and may explain why sports hernia is so symptomatic. Obturator nerve entrapment has been described by Bradshaw et al<sup>5</sup> as comparable to an anterior compartment syndrome of the lower extremity.

#### PHYSICAL EXAMINATION

The physical examination findings of athletic pubalgia are tenderness to palpation over the pubic crest on resisted sit-up and pain on resisted adduction of the lower extremity. There is no cough impulse

**Figure 2:** Two layer #1 Prolene darn of posterior inguinal canal wall from Internal oblique to Poupart's ligament.



visible or palpable at the external inguinal ring. Hip joint range of motion is always assessed and a decreased range of internal rotation of the hip joint suggests a labral tear of the hip joint.

#### DIAGNOSTIC IMAGING

Imaging should start with plain radiographs of the pelvis in the erect anteroposterior (AP) view including flamingo stress views. Further imaging may include ultrasound, CT, magnetic resonance imaging (MRI) and radionuclear bone scan. Electromyography (EMG) can also be useful. Ultrasound and MRI are the tests most frequently used in the investigation, however plain radiography of the pelvis may often show signs of osteitis pubis, pelvic tilt and vertical pubic symphysis shift >2 mm on flamingo stress views indicating pelvic instability.

Dynamic real-time ultrasound is the basis of diagnosis of incipient direct inguinal hernia in athletes<sup>6</sup> but is very dependent on the skill of the operator. MRI provides excellent overall soft tissue and bone information but is not able to assess incipient hernia.

Osteitis pubis has well-defined radiographic features and may also be demonstrated on radionuclear bone scan. MRI shows a high correlation between bone marrow oedema and chronic groin pain which suggests that bone stress may be the primary sources of pain in athletic

pubalgia. Osteitis pubis usually resolves after groin reconstruction but this may take six to nine months for symptoms to resolve and two years to reverse bone oedema on MRI. Professor Per Holmich, an orthopaedic surgeon from Copenhagen, has 48 players involved in a longitudinal 10 to 12 year follow-up study in which the radiological findings of osteitis pubis have been reversed after active physiotherapy treatment (personal communication).

#### SURGERY

Groin reconstruction surgery achieves results by correcting imbalance across the pubic symphysis created by abnormal adductor and abdominal muscles and reducing compartment pressures. The most common surgical procedures performed are repair of the posterior inguinal canal wall (herniorrhaphy), conjoint tendon repair and adductor tenotomy usually performed in conjunction at the one operation.

The diagnosis of adductor tendinopathy merits adductor tenotomy as a form of management. In those patients measured, there is a 10% postoperative strength reduction which does not result in any obvious functional or speed limitation because other muscles in the adductor group, namely adductor brevis, adductor magnus and pectineus, take over its function. Adductor tenotomy has been successfully performed in rugby union wingers and football players without any

decrease in maximal sprinting speed. The operation is performed by releasing the anterior ligamentous fibres of the adductor longus while keeping the fleshy part of the muscle intact on the deep aspect, thus minimising the loss of adductor strength after surgery and constituting a template for future regrowth of the tendon.

A bilateral repair is undertaken in about 30% of cases but this has been as high as 90% in other series (Dr Moshe Dudai, Israel). The use of mesh in young people is discouraged because of the 3% incidence of long-term chronic groin pain and the risk of infertility due to mesh stenosis of the inguinal canal.

Femoro-acetabular impingement and acetabular labral tears require collaboration with a hip orthopaedic specialist who carries out arthroscopic labral debridement before the soft tissue reconstruction is undertaken.

#### SURGICAL TECHNIQUE

All patients undertake 'pre-habilitation' as advised by Dr O.J.A. Gilmore (London, UK) for two to three weeks before their surgery to ensure that they are in peak physical condition before surgery. Postoperatively, we follow the recommendation of Dr B. Todd Heniford and treat all patients with spirulina (essential amino acid supplement) 1 g three times a day, mineral supplementation of copper and zinc and antioxidant vitamins C, A and B<sup>6</sup>.



## HOW TO SUCCEED WITH SURGERY FOR ATHLETIC GROIN PAIN

- 1 Commit to excellence and meticulous surgery.
- 2 Find an experienced radiologist who shares your enthusiasm.
- 3 Don't operate unless you have all the diagnostic information you need.
- 4 Choose a team of anaesthetist, assistant, scrub nurse, etc of highest quality.
- 5 Ensure that your operative infection rate is negligible.
- 6 Don't use hernia mesh in young people because of future risks of chronic pain (mesh inguinodynia) and infertility.
- 7 Establish contacts with team sports physicians of every persuasion.
- 8 Assemble close contacts in the disciplines of orthopaedics, podiatry, physiotherapy, sports medicine and commit to a team approach.
- 9 Be obsessive in reporting your follow-up and use your colleagues as critical sounding boards for your work.

Anti-embolism stockings are worn as soon as the patient is admitted to the hospital ward and worn for two weeks postoperatively. During surgery, mechanical calf stimulation is performed by pneumatic calf compressors. All operations are performed under general anaesthetic with muscle relaxation. Antibiotic prophylaxis is given at the time of anaesthetic induction with a broad spectrum antibiotic.

The skin incisions are about 10 cm. Operative findings can include a shredding of the external oblique muscle, widening of the superficial inguinal ring, split in the conjoint tendon insertion, a dehiscence between the conjoint tendon and the inguinal ligament (sports hernia) and peripheral nerve entrapment either ilio-inguinal nerve in the external oblique aponeurosis or obturator nerve in the fascia deep to the adductor longus lying on the adductor brevis.

The surgical repair performed:

1. The conjoint tendon is approximated to the pubic crest from the pubic tubercle to the midline with #1 Prolene inverting sutures after opening the inguinal canal (Hyde technique).
2. The fascia transversalis is plicated with continuous #0 Prolene suture.
3. A #1 Prolene figure-of-eight Maloney dam is performed in two layers between the internal oblique muscle and the inverted edge of the inguinal ligament (Poupart's ligament).

4. The external oblique muscle is closed with #2/0 Monocryl.

Open adductor tenotomy is performed after the conjoint tendon repair and sports hernia repair under the same general anaesthetic. A 4 cm transverse incision is made parallel to the groin crease centred over the most proximal part of the adductor longus tendon. Tenotomy is performed about 2.5 cm from the insertion into the pubic bone and the fascia lata is closed over the divided tenotomy site to prevent adhesion of the cut tendon to the overlying subcutaneous tissue.

Operations are usually performed with an overnight hospital stay and postoperative analgesia is provided by Panadeine Forte® (Sanofi-Synthalabo Australia) and Tramal® (Grünenthal GmbH, Stolberg, Germany) orally.

Postoperative activity during the first week consists of power walking and stationary cycling and at the first postoperative visit one week after surgery, the three-month postoperative physiotherapy programme is commenced.

### References

1. Orchard JW, Read JW, Verrall GM, Slavotinek JP. Pathophysiology of chronic groin pain in the athlete. *International SportsMed Journal* 2000; 1.
2. Ekstrand J, Ringborg S. Surgery versus conservative treatment in soccer

players with chronic groin pain: a prospective randomized study in soccer players. *Eur J Sports Traumatol Rel Res* 2001; 23:141-145.

3. Paaanen H, Brinck T, Hermunen H, Airo I. Laparoscopic surgery for chronic groin pain in athletes is more effective than nonoperative treatment: a randomized clinical trial with magnetic resonance imaging of 60 patients with sportsman's hernia (athletic pubalgia). *Surgery* 2011; 150:99-107.
4. Orchard JW, Read JW, Anderson JJ. The use of diagnostic imaging in sports medicine. *Med J Aust* 2005; 183:482-486.
5. Bradshaw C, McCrory P, Bell S, Brukner P. Obturator nerve entrapment. A cause of groin pain in athletes. *Am J Sports Med* 1997; 25:402-408.
6. Orchard JW, Read JW, Neophyton J, Garlick D. Groin pain associated with ultrasound finding of inguinal canal posterior wall deficiency in Australian Rules footballers. *Br J Sports Med* 1998; 32:134-139.

John F. W. Garvey, B.Sc. (Med)  
M.B., B.S. (NSW)

D. Phil (Oxon) F.A.C.S., F.R.A.C.S.

General and Diagnostic Surgeon

Groin Pain Clinic, Sydney, Australia

Contact: [www.groinpainclinic.com.au](http://www.groinpainclinic.com.au)